

High Tibial Osteotomy and Ligament Reconstruction for Varus Angulated Anterior Cruciate Ligament-Deficient Knees*

Frank R. Noyes,† MD, Sue D. Barber-Westin, and Timothy E. Hewett, PhD

From the Cincinnati Sportsmedicine and Orthopaedic Center and the Deaconess Hospital, Cincinnati, Ohio

ABSTRACT

In a consecutive series, we treated 41 young patients who had anterior cruciate ligament deficiency, lower limb varus angulation, and varying amounts of posterolateral ligament deficiency. Seventy-three percent of the patients ($N = 30$) had lost the medial meniscus and 63% ($N = 26$) had marked articular cartilage damage in the medial compartment. All patients were treated with high tibial osteotomy and, in the majority ($N = 34$), anterior cruciate ligament reconstruction a mean of 8 months later. Posterolateral reconstructions were also required in 18 knees. A 100% follow-up was obtained at a mean of 4.5 years after osteotomy. Gait analysis testing was done in 17 knees before and after osteotomy. At follow-up, a reduction in pain was found in 71% (29 knees); elimination of giving way, in 85% (35 knees); and resumption of light recreational activities without symptoms, in 66% (27 knees). The patient rating of the knee condition was normal or very good in 37% (15 knees) and good in 34% (14 knees). The mean Cincinnati Knee Rating Score significantly improved from 63 to 82 points. The mean adduction moment, 35% higher than controls preoperatively, significantly decreased to below normal values postoperatively. Correction of varus alignment was maintained in 33 knees (80%). We recommend osteotomy in addition to ligament reconstructive procedures in these knees with complex injury patterns.

High tibial osteotomy has gained acceptance as a treatment option for young patients with lower extremity varus osseous malalignment and symptomatic medial tibiofemoral compartment arthrosis. Patients with this knee deformity generally have better results when the osteotomy is performed early in the arthrosis process, before the exposure of subchondral bone in the medial tibiofemoral compartment.^{7,13,30} Partial to complete loss of the medial meniscus is a significant factor in physiologically varus aligned knees in terms of the early onset of medial compartment arthrosis and poor functional outcomes, even after high tibial osteotomy.^{5,15,26} The decisions regarding treatment for young patients with these abnormalities become more difficult when ligament deficiencies are present.

To classify the anatomic abnormalities of these knees, we previously devised the terms primary-, double-, and triple-varus knee syndromes.²⁷ These terms take into account the underlying tibiofemoral osseous and geometric alignment, abnormal knee motion limits, abnormal knee joint positions (subluxations), and specific ligament defects (Fig. 1). *Primary varus* refers to the tibiofemoral osseous alignment and geometry at the knee joint including the added varus alignment that occurs with loss of the medial meniscus and damage to the articular cartilage in the tibiofemoral joint.⁴ In varus angulated knees, it is well appreciated that the lateral soft tissue restraints may become slack, allowing for increased lateral joint opening. In these situations, separation of the lateral tibiofemoral compartment occurs with activity (lateral condylar lift-off).^{12,35} The term *double varus* was coined for these knees because the lower limb varus alignment occurs because of two factors: the tibiofemoral osseous alignment and separation of the lateral tibiofemoral compartment due to deficiency of the lateral soft tissues. Chronic excessive tensile forces in the posterolateral ligament structures, or traumatic injury, may further result in a varus recurva-

* Presented at the 66th annual meeting of the American Academy of Orthopaedic Surgeons, Anaheim, California, February 1999.

† Address correspondence and reprint requests to Frank R. Noyes, MD, Deaconess Hospital, 311 Straight Street, Cincinnati, OH 45219.

No author or related institution has received any financial benefit from research in this study. See "Acknowledgment" for funding information.

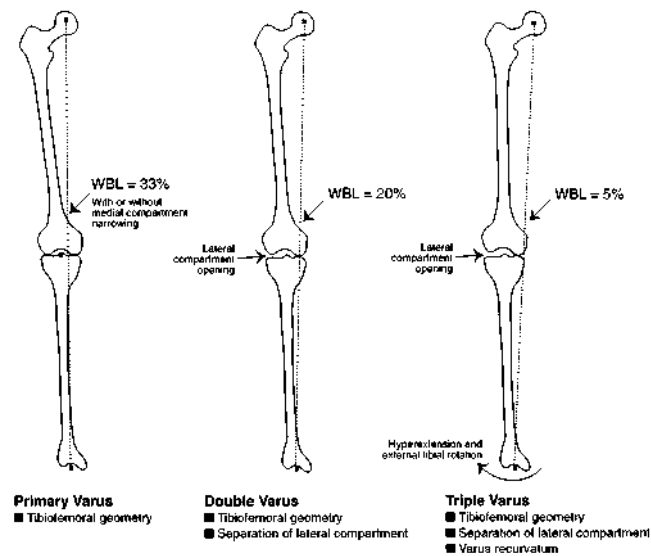


Figure 1. Categories of varus angulation based on cause (see text for details). WBL, weightbearing line.

tum position.⁸ This condition is referred to as *triple varus*, where the varus alignment occurs because of three factors: tibiofemoral osseous alignment, marked separation of the lateral tibiofemoral compartment, and increased external tibial rotation and hyperextension with an abnormal varus recurvatum position.

Patients with double- or triple-varus knee syndromes often have instability symptoms related to ACL deficiency, pain symptoms originating from the medial compartment arthrosis, and varus or hyperextension gait abnormalities. We previously reported the altered gait characteristics that may be present, including decreased external knee flexion moments, high external adduction moments, increased external knee extension moments, and increased knee hyperextension during stance phase.^{23,26}

The purpose of this investigation was to prospectively assess the outcome of operative treatment for these complex abnormalities in a consecutive series of patients who had combined high tibial osteotomy and ligament reconstructive procedures. Second, we sought to determine the magnitude of external knee moments before and after

high tibial osteotomy and to assess the ability of the operative procedures to restore normal gait characteristics. This represents the first report in the English literature that we are aware of to determine the outcome of operative treatment in patients with double- and triple-varus knee syndromes.

MATERIALS AND METHODS

Subjects

To be included in this study, patients had to have varus malalignment treated by high tibial osteotomy, ACL deficiency treated by bone-patellar tendon-bone graft reconstruction, and partial to complete lateral ligament deficiency. We excluded patients with posterior cruciate or medial ligament deficiency and ACL ruptures reconstructed with other types of grafts. A total of 41 knees (23 double varus, 18 triple varus) met these criteria (Table 1). A 100% follow-up was obtained at a mean of 4.5 years (range, 2 to 12) after the osteotomy. The majority of patients ($N = 32$) sustained the original knee injury during sports, and all except two had at least one operative procedure before the high tibial osteotomy (Table 2). Before referral to our center, 15 patients had had 19 ACL reconstructions that had failed. Thirty patients (73%) had had a partial or total medial meniscectomy before the osteotomy.

Evaluation and Overall Rating

All patients were interviewed for the subjective and functional analysis using the Cincinnati Knee Rating System² by an unbiased observer. An overall rating score was calculated preoperatively and at follow-up for each patient. Modification of the rating of symptoms was required as previously described.¹⁵ Patients rated the overall condition of the knee on a numeric scale by circling a number from 1 (poor) to 10 (normal) that best represented the knee condition.

A KT-2000 arthrometer (MEDmetric Corp., San Diego, California) was used to test instability with 134 N of total anterior-posterior force. Arthrometry testing was done by one experienced examiner preoperatively and at intervals

TABLE 1
Patient Characteristics and Timing of Operative Procedures and Follow-up (Means and Ranges)

Variable ^a	Double-varus knees ($N = 23$)	Triple-varus knees ($N = 18$)
Age at HTO (years)	30 (19–47)	28 (16–46)
Men (number)	21	11
Women (number)	2	7
Time from original knee injury to HTO (months)	98 (4–255)	48 (4–176) ^b
Operative procedures before HTO (number)	3.2 (1–6)	4 (0–11)
Time from HTO to ACL reconstruction (months)	6 (0–31)	7 (0–44) ^c
Time from HTO to follow-up (months)	57 (28–143)	52 (23–100)
Time from ACL reconstruction to follow-up (months)	48 (23–130)	50 (19–99)

^a HTO, high tibial osteotomy.

^b Significant difference between double- and triple-varus knees ($P < 0.01$).

^c Four patients who had ACL reconstruction done before HTO were not included.

TABLE 2
Operative Procedures Undergone by Patients Before High Tibial Osteotomy

Procedure	Double-varus knees	Triple-varus knees
Arthroscopy	32	36
Medial meniscectomy, partial or total	24	10
ACL reconstruction	9	10
Lateral meniscectomy, partial	5	4
Meniscus allograft or repair	2	2
Lateral collateral, posterolateral reconstruction	0	4

postoperatively in all patients except seven who had bilateral ACL ruptures.³⁸ The results of the arthrometry and pivot shift tests were used to classify the results of the ACL reconstructions as functional, partially functional, or failed based on a previously described system.²¹

For the lateral and posterolateral structures, the results of the manual varus stress test (lateral joint opening at 25° of flexion), external tibial rotation test,⁵ and varus recurvatum tests were combined to produce a rating of functional, partially functional, or failed.¹⁸ A functional classification was given when less than 3 mm of increase in lateral joint opening and less than 5° of increase in external tibial rotation were detected. A partially functional classification was given when between 3 and 5 mm of increase in lateral joint opening or 6° to 10° of increase in external tibial rotation was detected. A grade of failure was given if more than 5 mm of increase in lateral joint opening or more than 10° increase in external tibial rotation was detected.

Gait Evaluation and Preoperative Planning

The methods for our preoperative evaluation and surgical planning have been previously described (Fig. 2).⁴ The patients' gait during walking was observed for a varus thrust or hyperextension position during stance phase.²³ Seventeen patients (12 double varus and 5 triple varus) consented to gait analysis testing both before and at a mean of 2 years after the high tibial osteotomy. Patients who had preoperative gait testing but did not undergo follow-up testing were excluded from this analysis. The GaitLink system (Computerized Functional Testing Corporation, Chicago, Illinois) included a two-camera, video-based optoelectronic digitizer for measuring motion and a multicomponent force plate (Bertec, Columbus, Ohio), camouflaged under a 10-meter walkway, for measuring ground-reaction force. The measurements were obtained by a microcomputer-based data acquisition system and were processed remotely.^{1,31} For this study, a control population of 28 age- and sex-matched normal subjects was used for comparisons. All moments were normalized to the product of body weight multiplied by height and were expressed as a percentage of that product. All patients who had postoperative gait testing had normal knee motion of at least 0° to 135° and no knee arthrofibrosis. A mathematical model was used to predict the joint reaction

loads, lateral soft tissue forces, and muscle forces as described previously.²⁶

A radiographic evaluation was performed from double-stance, full-length films in which the weightbearing line and mechanical axis were determined using a method previously described.⁴ The medial joint space narrowing was evaluated by posteroanterior weightbearing views taken at 45° of knee flexion.³³

Articular Cartilage

The articular surfaces of the patellofemoral and tibiofemoral joints were classified according to a previously described system.²⁸ Lesions were classified as abnormal if fissuring and fragmentation extended to at least one-half the depth of the articular surface (grade 2B) over an area of at least 15 mm or if subchondral bone was exposed (grade 3).

Thirty knees had abnormal articular cartilage lesions. In 18 knees, 1 compartment was affected; and in 12 knees, 2 compartments (patellofemoral and medial tibiofemoral) were affected.

Twenty-six knees (63%) had lesions in the medial compartment. In 8 knees, grade 3 lesions were found; and in 18 knees, grade 2B lesions were noted. In 11 knees, both the femur and tibia were affected; and in 15 knees, only the femur was affected. Twenty-one of these knees had previously had a partial or total medial meniscectomy. Sixteen knees had lesions in the patellofemoral compartment.

Operative Procedures

In 21 (91%) of the double-varus knees the ACL was reconstructed a mean of 9 months after the high tibial osteotomy, and in 2 knees the osteotomy and ACL reconstruction were done simultaneously. Thirteen knees operated on between 1984 and 1990 had ACL allograft reconstruction, and 10 knees operated on after 1990 had ACL autograft reconstruction. This change in graft selection was due to the initiation of a prospective study in 1991 where all ACL reconstructions were done using bone-patellar tendon-bone autografts.¹⁶ In five knees fresh-frozen irradiated medial meniscus allografts were implanted during the ACL reconstruction.²⁰ All of these knees had significant articular cartilage damage to the medial tibiofemoral compartment, prior total medial meniscectomies, and prolonged medial joint pain; all of these were indications for a meniscus allograft procedure according to the study protocol at that time.²⁰

In 13 (72%) of the triple-varus knees, the ACL was reconstructed a mean of 8 months after the osteotomy. One patient had the osteotomy and ACL reconstruction done simultaneously. Four patients had the ACL reconstruction done before the osteotomy in an attempt to avoid the osteotomy. Eight knees had ACL allografts and 10 had ACL autografts. In one knee, a meniscus allograft was implanted at the time of ACL reconstruction.

All triple-varus knees had reconstruction of the posterolateral structures; 12 (67%) had a proximal advancement

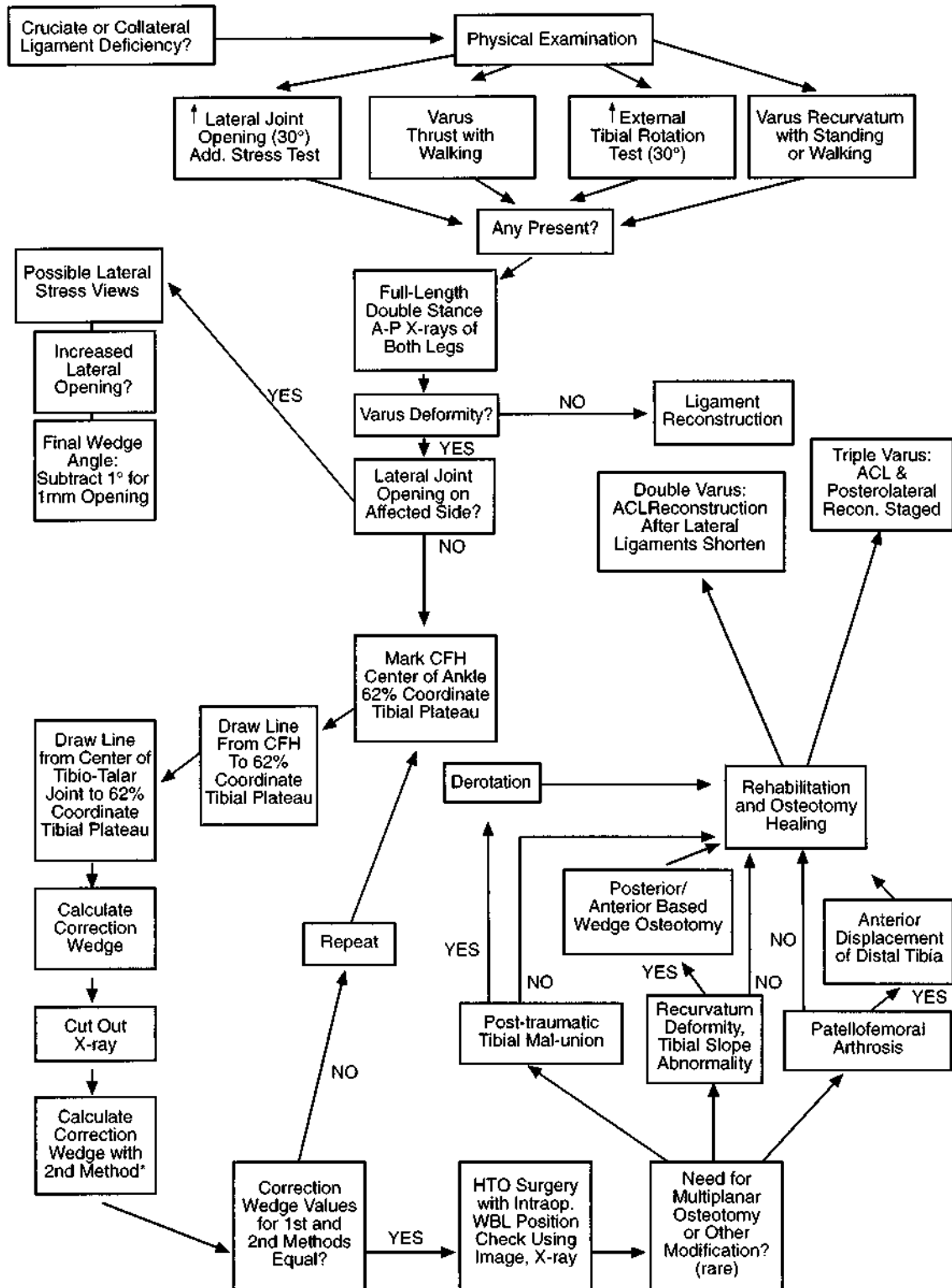


Figure 2. Algorithm for the diagnosis and treatment of young, athletic patients with varus angular alignment and injury to the lateral ligaments and soft tissues. CFH, center femoral head. HTO, high tibial osteotomy; WBL, weightbearing line. * 2nd Method, measure angle of tibial radiograph cut at level of osteotomy to achieve 62% coordinate on the tibial plateau. (Reprinted with permission from Dugdale TW, Noyes FR, Styer D: Preoperative planning for high tibial osteotomy: The effect of lateral tibiofemoral separation and tibiofemoral length. *Clin Orthop* 274: 246-264, 1992)

of the posterolateral complex¹⁸ with the ACL reconstruction, and 6 had an allograft procedure¹⁹ (5 with the ACL, 1 with the osteotomy). The knees that had the proximal advancement procedure had a definite, although lax, lateral collateral ligament of normal width and integrity and also had intact popliteal muscle-tendon and popliteal fibular attachments that were previously described as an indication for this procedure.¹⁸ The knees that had allograft reconstruction had extensive damage to the posterolateral tissues; the indications and techniques have been previously described.¹⁹

The goal of the high tibial osteotomy was to align the weightbearing axis of the lower limb so that it passed through the 62% coordinate of the width of the tibial plateau (0% corresponded to the medial border of the tibial plateau and 100% corresponded to the lateral border).^{4,15} A proximal tibial closing wedge osteotomy was done with the aid of a commercially available cutting jig system (NexGen Osteotomy System, Zimmer, Warsaw, Indiana). Internal plate fixation was accomplished with an L-shaped five-hole buttress plate, two 6.5-mm cancellous bone screws in the proximal tibia, and two to three cortical screws distal to the osteotomy.^{25,27} Disruption of the proximal tibiofibular joint was avoided to prevent proximal migration and laxity in the posterolateral structures. An osteotomy of the fibula was performed at the fibular neck, with bone removed to allow for compression at the fibular osteotomy site. An image intensifier was used at surgery to measure the weightbearing line during axial loading of the joint to ensure the 62% coordinate had been achieved.

Postoperative Rehabilitation

The protocols for rehabilitation after high tibial osteotomy, ACL reconstruction, and posterolateral structure reconstruction have been previously described in detail.^{16,18,27} The rehabilitation program after the osteotomy included immediate range of motion (0° to 90°), quadriceps muscle isometric exercises, straight leg raises, patellar mobilization, and electric muscle stimulation. For the 1st week after surgery, ice, mild compression, and elevation were used to prevent edema and swelling. Patients were ambulatory for short periods of time but were instructed to elevate their limb, remain home, and not resume usual activities. Prophylaxis for deep vein thrombosis included intermittent compression stocking boots the 1st night after surgery, antiembolism stockings, ankle pumps, and aspirin (600 mg once a day for 3 weeks).

A Bledsoe long-leg brace (Bledsoe, Grand Prairie, Texas) was worn for the first 8 postoperative weeks. Patients were allowed toe-touch weightbearing for the first 3 weeks to prevent excessive forces at the osteotomy site. Weightbearing was gradually increased to full by the 8th to 10th postoperative week if radiographs demonstrated adequate healing and maintenance of the osteotomy position. The protocol emphasized strengthening of the quadriceps, hamstring, hip, and gastrocnemius-soleus musculature. Closed-chain exercises and stationary bicycling were be-

gun at the 5th postoperative week, and weight-machine exercises were begun at the 7th to 8th postoperative week. Excessive use of bicycling and weight machines was not allowed in patients with articular cartilage damage. By the 9th to 12th postoperative week, other aerobic conditioning exercises were begun as appropriate, including swimming, ski machines, and walking.

Patients who had reconstruction of the posterolateral structures had immediate knee motion and maximal protection against undue joint loads to prevent failure. Patients were warned to avoid knee hyperextension positions and varus loads that could place excessive forces on the posterolateral reconstruction. A Bledsoe postoperative brace was worn locked at 0° of extension at all times to protect the posterolateral reconstruction, except during range of motion exercises done four times daily for the first 4 weeks. Full knee motion was then allowed. On return to full weightbearing (12th postoperative week), a Bledsoe custom medial thruster brace was worn to provide additional protection to the posterolateral structures during gait and to prevent excessive opening of the lateral tibiofemoral compartment. Patients were allowed 0° to 90° of knee flexion immediately after surgery, with flexion slowly advancing to 130° by the 12th postoperative week. Patellar mobilization, flexibility exercises, and strengthening and conditioning programs were similar to those used after osteotomy.

Patients who expressed the desire to return to strenuous sports activities were advised of the risk of further cartilage deterioration if damage was present during any of the surgical procedures, and they were given medical consent only when muscle strength tests showed the strength of the quadriceps muscles on the involved limb was at least 70% that of the contralateral limb and no pain or swelling were incurred during or after activities. We strongly recommended to the majority of patients in this study a return to only light recreational sports activities and avoidance of high-impact athletic activities.

Statistical Analyses

The preoperative and follow-up data for the double- and triple-varus knees were compared to determine the effect of the various anatomic abnormalities on selected objective and subjective variables. The results of anterior-posterior displacement and pivot shift testing for knees that had ACL autogenous reconstructions were compared with those for knees with allograft reconstructions. Statistical tests used included chi-square and contingency table analyses and Student's unpaired *t*-tests, with alpha level less than 0.05 selected for significance.

There was no significant difference found between the double- and triple-varus knees for multiple comparisons, including 20 demographic and preoperative variables and 18 follow-up variables. Examples of these comparisons are shown in Table 3. The data were therefore combined for the analysis of outcome in the 41 knees.

TABLE 3
Demographic, Preoperative, and Follow-up Comparisons Between Double- and Triple-Varus Knee Subgroups (Means ± SD)

Variable ^a	Demographic/Preoperative		Follow-up	
	Double varus	Triple varus	Double varus	Triple varus
Age (years)	30 ± 7	28 ± 9		
Time from injury to HTO (months)	98	48 ^b		
Prior operative procedures (no.)	3.2 ± 1.5	4.0 ± 3.0		
Anterior-posterior displacement (mm)	12.7 ± 3.6	12.4 ± 5.8	2.9 ± 5.2	2.7 ± 5.5
Overall rating score (0–100 points)	62 ± 11	64 ± 12	82 ± 15	83 ± 12
Pain score (0–6 points)	2.9 ± 0.9	2.3 ± 0.9	5.2 ± 1.7	5.0 ± 1.7
Swelling score (0–6 points)	3.2 ± 0.9	2.7 ± 0.9	5.3 ± 1.1	5.1 ± 1.2
Partial giving way score (0–6 points)	2.8 ± 1.0	2.6 ± 0.8	5.7 ± 0.7	5.2 ± 1.4
Full giving way score (0–6 points)	3.1 ± 1.0	2.9 ± 1.0	5.7 ± 0.9	5.4 ± 0.9
Patient grade score (0–10 points)	3.9 ± 2.3	3.5 ± 1.7	5.9 ± 1.7	5.7 ± 1.9
Walking score (0–40 points)	30.9 ± 9.9	28.9 ± 10.2	36.1 ± 6.5	35.5 ± 9.8
Stair climbing score (0–40 points)	26.9 ± 13.9	25.0 ± 13.4	31.7 ± 13.3	31.1 ± 12.3
Running score (40–100 points)	53.9 ± 22.1	52.5 ± 21.8	64.3 ± 24.8	66.7 ± 21.7
Jumping score (40–100 points)	51.3 ± 17.9	47.8 ± 15.5	61.7 ± 24.1	65.5 ± 22.5
Cutting score (40–100 points)	45.2 ± 12.4	45.5 ± 11.5	59.1 ± 22.9	63.3 ± 24.0
Mechanical axis (degs)	-1.6 ± 6.3	-4.4 ± 5.7	1.3 ± 2.7	2.0 ± 3.1
Follow-up (months)			57	52
Follow-up operative procedures (no.)			3.7 ± 2.2	3.0 ± 2.2

^a HTO, high tibial osteotomy.

^b Significant difference between double- and triple-varus knees (*P* = 0.01).

RESULTS

Symptoms, Function, and Activity Level

At follow-up, statistically significant improvements were found for pain, swelling, and giving way (*P* < 0.001) (Fig. 3). Before the high tibial osteotomy, 18 patients (44%) had severe-to-moderate pain with activities of daily living, whereas at follow-up only 7 patients (17%) had pain with these activities. Overall, 29 patients (71%) had improved pain scores and 28 patients (68%) had improved swelling and giving-way scores.

At follow-up, statistically significant improvements were found for the activities of daily living functions (*P* <

0.05) (Fig. 4). Preoperatively, 10 patients (24%) had severe problems with normal walking, 13 patients (32%) had limitations with stair climbing, and 25 patients (61%) had severe difficulty squatting. At follow-up, only 3 patients (7%) continued to have problems with walking; 5 patients (12%), with stair climbing; and 10 patients (24%), with squatting.

At follow-up, statistically significant improvements were found for the sports functions (*P* < 0.05) (Fig. 5). Preoperatively, only 9 patients (22%) could run with no or only slight limitations, and at follow-up 16 patients (39%) could run with no or only slight limitations. Preoperatively, 14 patients (34%) participated in sports

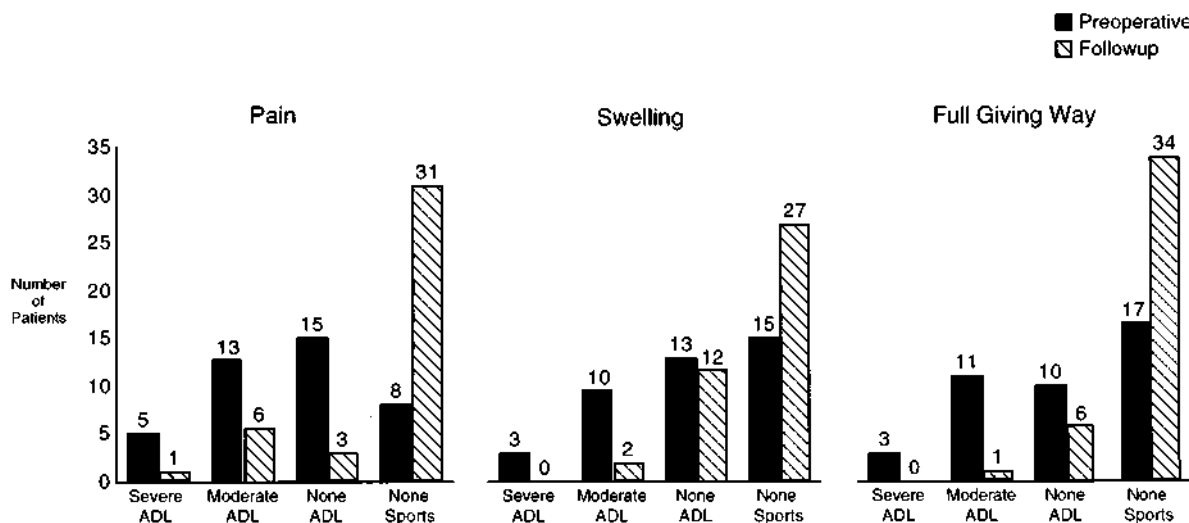


Figure 3. Statistically significant improvements were found for pain, swelling, and giving way from preoperative to follow-up (*P* < 0.01). ADL, activities of daily living.

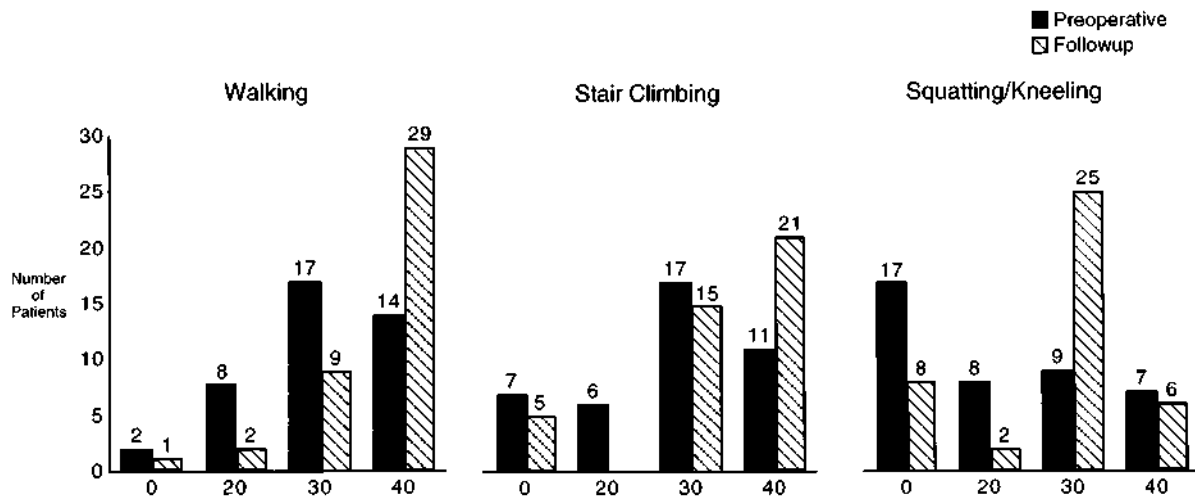


Figure 4. Statistically significant improvements were found for walking, stair climbing, and squatting/kneeling from preoperative to follow-up ($P < 0.05$). Walking scale: 0, less than 1 block; 20, only 3 to 4 blocks possible; 30, some limitations; 40, normal, unlimited. Stairs: 0, only 1 to 10 steps possible; 20, only 11 to 30 steps possible; 30, some limitations; 40, normal, unlimited. Squatting/kneeling: 0, only 0 to 5 possible; 20, only 6 to 10 possible; 30, some limitations; 40, normal, unlimited.

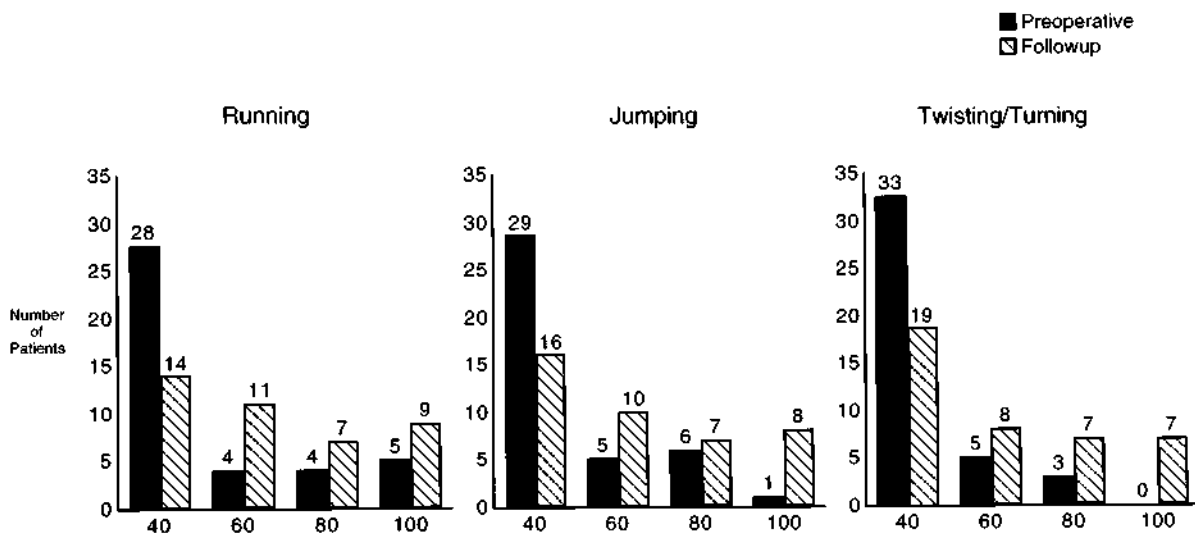


Figure 5. Statistically significant improvements were found for running, jumping, and twisting/turning from preoperative to follow-up ($P < 0.05$). Scale: 40, not able to do; 60, definite limitations, half-speed; 80, some limitations, guarding; 100, fully competitive.

activities, all of whom had symptoms (Table 4). At follow-up, 27 patients (66%) had returned to athletics without symptoms. Most patients were participating in light swimming or bicycling activities only, based on our advice.

Twenty-three patients were employed before the osteotomy procedure: 11 in light occupations with no problems, 9 in moderate occupations with symptoms, and 3 in very heavy occupations with symptoms. Nine other patients were disabled, and nine were students or homemakers. At follow-up, 34 patients were employed: 20 in light occupations with no problems, 10 in moderate occupations of whom 5 were symptomatic, and 4 in very heavy occupa-

tions of whom 3 were symptomatic. Three patients were disabled and 4 were students or homemakers.

Overall Rating Scores and Patient Perception

Statistically significant improvements were found in the mean overall rating score from preoperative to follow-up (63 ± 11 points and 82 ± 14 points, respectively, $P = 0.0001$). The average increase was 20 ± 10 points (range, 2 to 39); no patient had a decrease in this score.

At follow-up, 1 patient rated his knee as normal; 14, as very good; 14, as good; 10, as fair; and 2, as poor. The mean score on the scale was 6 points (range, 2 to 9).

TABLE 4
Sports Activities for All Patients

Type of sport	Preoperative	Follow-up ^a
Jumping, pivoting, cutting	2 (5%)	3 (7%)
Running, twisting, turning	9 (22%)	4 (10%)
Swimming, biking	3 (7%)	24 (59%)
No Sports	27 (66%)	10 (24%)
Change in sports activities at follow-up		
Same level, no symptoms		1 (2%)
Increased level, no symptoms		19 (46%)
Decreased level, no symptoms		7 (17%)
Playing with symptoms		4 (10%)
No sports due to knee condition		9 (22%)
No sports due to non-knee-related reasons		1 (2%)

^a $P = 0.0001$, chi-square analysis.

Effect of Articular Cartilage Condition

There was no statistically significant difference at follow-up in either the pain scores or the patient rating scores between the 8 knees with exposed subchondral bone and the 18 knees with fissuring and fragmentation in the medial tibiofemoral compartment (Table 5). There was also no significant difference in these scores between patients who had abnormal cartilage surfaces in just one compartment and those who had abnormal cartilage surfaces in two compartments. The improvements for these scores from preoperative to follow-up were statistically significant for these four subgroups ($P < 0.01$).

Knee Examination and Stability

Preoperatively, all patients with double-varus knees had abnormal increases in lateral joint opening (mean, 4 mm; range, 2 to 10 mm). No increase in external tibial rotation was detected in 17 patients, and only mild increases of 5° were found in 6 patients. At follow-up, no patient had more than 2 mm of increase in lateral joint opening and none had an increase in external tibial rotation. All received functional ratings for the lateral and posterolateral structures.

Preoperatively, all of the triple-varus knees had varus recurvatum, increases in lateral joint opening (mean, 8 mm; range, 3 to 15), and increases in external tibial rotation (mean, 9°; range, 3° to 15°). At follow-up, 13 knees had a functional rating, 4 had partial function, and 1 failed.

Preoperatively, the triple-varus knees had hyperextension ranging from 5° to 20°. At follow-up, 16 knees had 0° of extension (without hyperextension) and 2 knees had

hyperextension of 5° and 15°, similar to that measured before the osteotomy. All 41 knees had at least 135° of flexion at follow-up.

Four patients required revision after early failure of the ACL allograft (three knees) or autograft (one knee) reconstruction (see "Follow-up Operative Procedures"). With inclusion of these revisions, a total of 45 ACL reconstructions were performed (23 allografts and 22 autografts). The decrease in the mean AP displacement measurements from preoperative (12.6 ± 4.7 mm) to follow-up (2.8 ± 5.3 mm) was statistically significant ($P = 0.0001$). At follow-up, 19 reconstructed knees (42%) were functional, 11 (24%) had partial function, and 15 (33%) had failed.

Ten (7 allografts and 3 autografts) of the 15 reconstructions that failed represented ACL revision cases. A statistically significant difference was found in the failure rate for ACL revision cases compared with primary reconstruction cases (67% and 33%, respectively, $P = 0.03$). There was no significant effect of ACL graft type on the failure rate, overall rating score, pain, or patient grade score (Table 6).

Gait Analysis Testing

There was no statistically significant difference in the mean preoperative adduction moment between the double-varus and triple-varus knees ($4.1\% \pm 0.3\%$ and $4.2\% \pm 0.3\%$, respectively). The preoperative and postoperative study and control group values of knee joint moments, compartment loads, and lateral ligament tensile forces are shown in Table 7. The preoperative mean adduction moment of the study group was 35% higher ($P < 0.001$) than that of the control group; 10 of the 17 patients (59%) had values that were greater than 1 standard deviation above control values (Fig. 6). The study group also had a 22% higher predicted medial compartment load, and a 40% higher lateral ligament tensile force, compared with the control group ($P < 0.01$). Above-normal medial compartment loads were predicted preoperatively in 71% of the involved knees, and above-normal lateral soft tissue forces during walking were predicted in 43% of the involved knees. Seven knees (41%) demonstrated a reduced external flexion moment.

Postoperatively, the adduction moment and lateral ligament tensile force decreased to significantly lower than control values. The medial compartment load decreased to values equal to those of controls (Fig. 7). Only three knees had a reduced external flexion moment.

TABLE 5
Results of Treatment in Knees With Abnormal Articular Cartilage

Type of abnormality	Postoperative pain	Postoperative patient grade
Exposed bone, medial compartment ($N = 8$)	5.0 ± 1.9	5.4 ± 1.9
Fragmentation, medial compartment ($N = 18$)	5.1 ± 1.7	5.9 ± 1.9
Unicompartmental ($N = 18$)	5.3 ± 1.7	6.3 ± 1.8
Bicompartmental ($N = 12$)	4.7 ± 1.8	5.2 ± 1.7

TABLE 6
Effect of ACL Graft Type on Results^a

Variable	Allografts	Autografts
AP displacement (mm)	4.1 ± 5.8	1.4 ± 4.4
ACL graft function (no.)		
Functional	7	12
Partially functional	6	5
Failed	10	5
Overall rating score	79 ± 15	86 ± 12
Pain score	4.8 ± 1.9	5.5 ± 1.3
Patient grade	5.7 ± 1.8	5.8 ± 1.8

^a There were no statistically significant differences between grafts for any variable.

Radiographic Evaluation of Alignment

Preoperatively, the mean weightbearing line was 22% (range, 3% to 49%) and the mean mechanical axis was -6.2° (range, -12° to -1°). At surgery, all knees were corrected to a weightbearing line of 62%. Early postoperative radiographs showed that two knees were in excessive valgus alignment (weightbearing line, 86%), and these patients subsequently underwent revision surgery (see "Follow-up Operative Procedures"). At follow-up, 33 knees (80%) were in an acceptable position (mean weightbearing line, 61%; range, 47% to 75%), 2 knees were in slight varus (40% to 45%), 5 knees were in marked varus (16% to 38%), and 1 knee was in excessive valgus (81%).

Patients with Meniscus Allografts

All six patients who received meniscus allografts reported improvements in the ratings for pain, giving way, and perception of the overall knee condition at follow-up. Statistically significant improvements were also found in the mean overall rating score between the preoperative and follow-up evaluations (61 ± 10 points and 82 ± 11 points, respectively, $P = 0.006$).

In two patients, arthroscopy and partial removal of symptomatic medial meniscus allografts were required 10 to 12 months postoperatively. In these two knees, only the inner one-third of the meniscus was removed to preserve

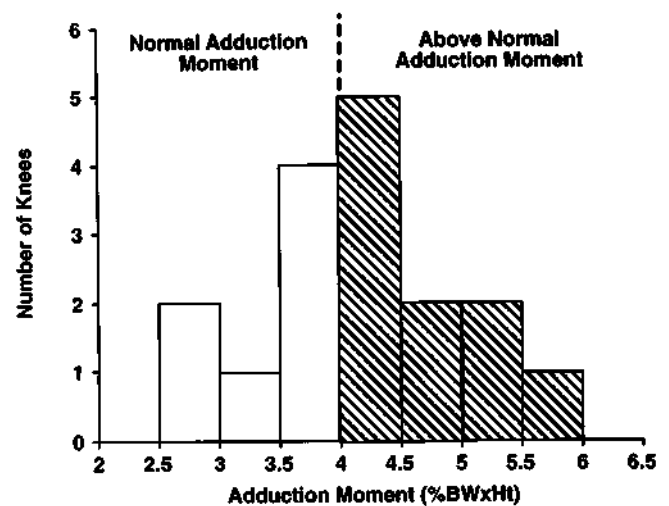


Figure 6. The distribution of the preoperative adduction moments of the 17 patients tested. The mean adduction moment for the study group was 35% higher than that for the control group ($P < 0.001$).

partial function of this structure. In one patient, two procedures were required to remove a symptomatic medial meniscus allograft. No further surgery was required in the other three knees.

Follow-up Operative Procedures

Additional surgery was performed in 14 knees (11 double-varus, 3 triple-varus). Two triple-varus knees required revision of the high tibial osteotomy. In both, the optimal correction to the 62% weightbearing line range was obtained and verified at surgery; however, excessive valgus positions (weightbearing line, 86%) occurred with full weightbearing. A revision high tibial osteotomy using a tibial opening wedge procedure was performed with a bone graft from the iliac crest 2 months postoperative in one knee and 6 months postoperative in the other. At

TABLE 7
Gait Analysis Data: Measured and Predicted Peak Values (Means ± SD)

Variable	Control group (N = 28)	Study group		
		Preoperative (N = 17)	Postoperative (N = 17)	Percentage change
Measured moment ^a				
Flexion	2.3 ± 0.8	2.2 ± 1.7	2.4 ± 1.3	+9
Extension	2.4 ± 0.7	1.5 ± 1.4	1.4 ± 1.1	-7
Adduction	3.1 ± 0.7	4.2 ± 0.8 ^b	2.6 ± 0.6 ^b	-38 ^c
Predicted tibiofemoral loads ^d				
Medial	2.3 ± 0.3	2.8 ± 0.3 ^b	2.2 ± 0.5	-21 ^c
Lateral	0.9 ± 0.3	1.1 ± 0.3	1.0 ± 0.4	-9
Predicted ligament tensile force ^d				
Lateral	0.5 ± 0.2	0.7 ± 0.2 ^e	0.3 ± 0.2 ^e	-57 ^c

^a Percentage of body weight times height.

^b Significantly different from control subjects ($P < 0.01$).

^c Significantly different between preoperative and postoperative values ($P < 0.01$).

^d Percentage of body weight.

^e Significantly different from control subjects ($P < 0.001$).

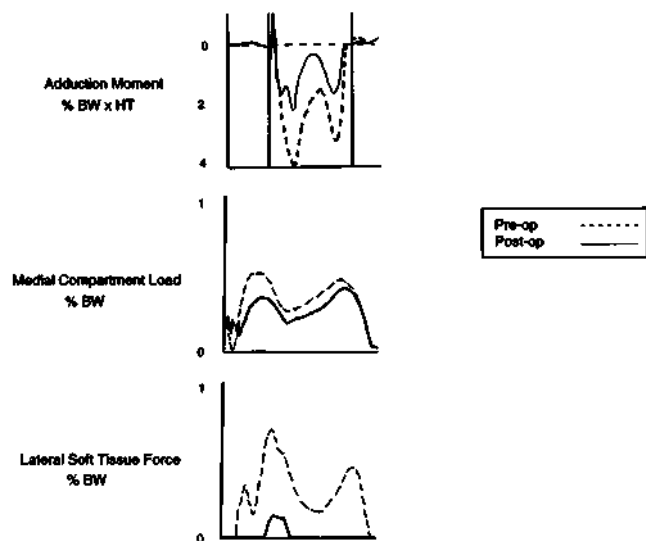


Figure 7. The preoperative and postoperative adduction moment, medial compartment load, and lateral ligament tensile forces for the 17 patients tested. Postoperatively, the adduction moment and lateral ligament tensile force decreased to significantly lower than control values. The medial compartment load decreased to values equal to those of controls. %BW, percent body weight; HT, height.

follow-up, one knee had maintained the optimal weight-bearing line position, but the other had resumed a varus position (40%).

One double-varus knee had a loss of internal fixation of the osteotomy at the 4th postoperative week that was corrected. The osteotomy healed without difficulty. Two patients required resection of a distal fibular painful non-union osteotomy site 12 and 26 months postoperatively.

In three patients, an early postoperative increase in AP displacement was noted and treated with a refixation of the autograft at the tibial site 4 to 6 weeks postoperatively. Four other patients required revision of the ACL reconstructions. One patient had a reinjury 4 years after the allograft reconstruction and required a bone-patellar tendon-bone autograft revision. Two patients with allograft reconstructions required repeat bone-patellar tendon-bone allograft procedures because of early failure postoperatively. The fourth patient had good stability restored for 3 years postoperatively but then noted a gradual increase in instability symptoms. A revision reconstruction was performed with a quadriceps tendon-bone autograft. Three knees required partial or total resection of symptomatic meniscus allografts, as previously described.

Complications

There was no evidence of infection, peroneal nerve palsy, patella infera, or knee motion limitations at follow-up. No patient required additional treatment intervention for losses of knee flexion or extension. At the time of writing, there was no evidence of allograft rejection or disease transmission.

DISCUSSION

The knees in this study included some of the most difficult diagnostic and treatment dilemmas that the clinician may be required to manage. As such, there were inherent problems that included a nonhomogenous population that had varying amounts of medial tibiofemoral arthrosis, differences in the condition of the medial menisci, two types of ACL grafts used for reconstruction, and differences in the amount of lateral and posterolateral ligament deficiency resulting in either nonoperative or operative treatment. We attempted to sort for these variations to determine whether differences existed between various subgroups. The small number of patients in each group precludes definitive conclusions, and we acknowledge that both these and additional patients with double- and triple-varus knees must be observed to determine the long-term results of our treatment. With these issues in mind, we believe the treatment protocol in this study improved the quality of life in the majority of patients. A reduction in pain was found in 71%, elimination of giving way was reported in 85%, and resumption of light recreational activities (based mostly on our advice) without symptoms occurred in 66%. Thirty-seven percent of the patients rated their knees as very good or normal and 34% as good. All regained normal range of knee motion without additional treatment intervention.

In 1985, we first reported on the double- and triple-varus knee syndrome, using these terms to highlight to the clinician the osseous and ligament abnormalities that contribute to the symptomatic state (F. R. Noyes et al., unpublished data). The varied clinical presentation of the patients underscores the methodical evaluation required to diagnose all of the anatomic abnormalities.^{22,29} The patellofemoral joint is assessed for alignment, which may be altered from increased external tibial rotation or symptomatic from articular cartilage damage. There may be medial tibiofemoral crepitus indicating damage to joint surfaces²⁴; gait abnormalities of a varus or hyperextension thrust during stance phase; muscular weakness or imbalance²³; and complications from prior surgery including scar formation, skin, neuroma, or hypersensitivity conditions.

Many of the patients in this study were first seen with a chronic ACL-deficient knee that had a prior medial meniscectomy with an underlying physiologic varus alignment present in both lower extremities. The patients complained of medial joint pain with sports or daily activities. In some, an ACL reconstruction had relieved instability symptoms but not medial joint pain and the varus thrust continued during gait and sports activities. Some patients were aware of a gradually increasing varus alignment, particularly during running, where varus thrust was pronounced. The patients involved in athletics frequently desired treatment to allow continuation of an active lifestyle, which was often unrealistic because of joint arthrosis. Other patients were aware of the seriousness of the knee condition and simply desired a symptom-free state with daily activities. In some of the triple-varus knees, the injury to the posterolateral structures may not have ini-

tially been complete. However, recurrent giving-way episodes or a continued varus thrusting gait over time may have produced tensile overload of the lateral soft tissues and a complete deficiency of the posterolateral structures. Fifteen of 41 knees in this series had a prior ACL reconstruction that had failed; many of these failures were due to an unrecognized posterolateral ligament injury.

The majority of patients in this series required extensive preoperative rehabilitation to improve the strength and function of the lower extremity muscles. Knees that had hyperextension gait abnormalities required gait retraining.²³ Patients were frequently surprised by the marked improvement in gait and decrease in joint pain after this program. Without preoperative retraining, patients would probably resume the hyperextension gait after surgery, which would place high tensile forces on the reconstructed ligament structures and risk failure. The physician-therapist team approach was required to assist the patients continually through the rather prolonged physical therapy course.

The preoperative evaluation and establishment of the treatment plan involved extensive patient education and counseling on the goals of the recommended surgical procedures. Often there were unrealistic goals on the outcome of surgery and the ability of the patient to return to strenuous athletics. In this study, 73% of knees had total or near-total meniscectomy, and 63% had marked articular cartilage damage in the medial compartment. The symptomatic state with daily activities makes it difficult to determine with accuracy the ability of the patient to resume daily activities without symptoms, let alone athletics. Earlier treatment of the instability and varus malalignment and retention of the medial meniscus should improve the prognosis in these knees.

We previously reported the procedures to follow in obtaining hip-knee-ankle standing radiographs and correctly calculating the angular wedge correction of the tibia to achieve a valgus overcorrection (weightbearing line of 62%).⁴ The treatment algorithm in Figure 2 shows the steps to take in calculating the tibiofemoral varus osseous alignment with subtraction of that component of varus alignment due to abnormal lateral joint opening. This calculation helps prevent a valgus overcorrection postoperatively, which occurs when the lateral tibiofemoral compartment resumes a closed configuration after the osseous malalignment is corrected. During the surgical procedure, an alignment rod is placed from the hip to the ankle to identify by fluoroscopy the weightbearing line at the tibia and the angular correction that has been achieved. The lower limb is positioned at 5° to 10° of flexion, and axial compression is performed to close both the medial and lateral tibiofemoral compartments. Appropriate adjustments at the site of high tibial osteotomy can be performed, if necessary, before internal tibial fixation. It is still not possible to tell with certainty what the final alignment of the lower limb will be when full weightbearing is resumed. In two knees in this study, a valgus overcorrection occurred when full weightbearing was resumed postoperatively and there was complete closure of the lateral tibiofemoral compartment.

In varus aligned knees with normal cartilage in the medial compartment, the osseous alignment is corrected to a neutral position without valgus overcorrection (weightbearing line, 50%). The restoration of normal tibiofemoral alignment corrects the varus thrust and allows for a decrease in the abnormally high lateral ligament tensile forces. Thus, the lateral compartment does not open during weightbearing.

There are three reasons why high tibial osteotomy may not achieve the desired valgus alignment. The first is the inability to achieve the desired correction of the weightbearing line at surgery. This is the only variable truly under the surgeon's control, and it should always be determined with an image intensifier on completion of the procedure. The second possibility for undercorrection is that certain knees with advanced medial tibiofemoral arthrosis may remain in varus alignment because of a tibial teeter-totter effect (advanced medial tibiofemoral arthrosis and obliquity), as the lateral tibiofemoral joint remains open.¹¹ The third possibility for undercorrection is a gradual collapse of the medial compartment over years in which the overall alignment drifts back into varus because of continued medial tibiofemoral arthrosis. Unfortunately, the latter two possibilities for undercorrection are not under the surgeon's control. Short-term symptoms may decrease, but it is doubtful that long-term benefits of the high tibial osteotomy will be obtained.

Five knees (12%) in this study had a varus alignment a mean of 4.5 years postoperatively. These five patients had an improvement in symptoms and therefore revision osteotomies were not performed; however, the ideal valgus alignment was not achieved. The rates of recurrence of varus alignment reported by other authors appear to increase with the amount of time from surgery. Dejour et al.³ reported an 11% undercorrection rate (5 of 44 knees) a mean of 3.5 years after surgery. Ivarsson et al.⁹ reported a 31% undercorrection rate (25 of 81 knees) a mean of 5.7 years after surgery. Hernigou et al.⁶ observed 76 patients for a mean of 11.5 years after surgery and reported that most had changes in alignment over time toward varus; 34 knees (45%) were in varus at the final evaluation.

The osteotomy technique we usually perform is a closing wedge tibial and fibular osteotomy (proximal fibular neck).³⁴ We preserve the proximal tibiofibular joint to maintain normal posterolateral ligament insertion lengths and to prevent proximal migration of the fibula, which would produce laxity of posterolateral structures. We also have clinical experience with opening wedge tibial osteotomy, for which the primary indications are simultaneous medial ligament instability that requires correction or the need for large angular corrections (greater than 12°) to prevent excessive tibial shortening or patella alta. Both the high tibial osteotomy and the medial ligament distal advancement or reconstruction are performed through the same incision. We prefer the closing wedge osteotomy, which avoids the necessity for an iliac crest bone graft, because osseous union and more rapid rehabilitation with earlier full weightbearing are possible with the two cancellous surfaces compressed and in full contact (Fig. 8).

The preoperative gait analysis showed an abnormally

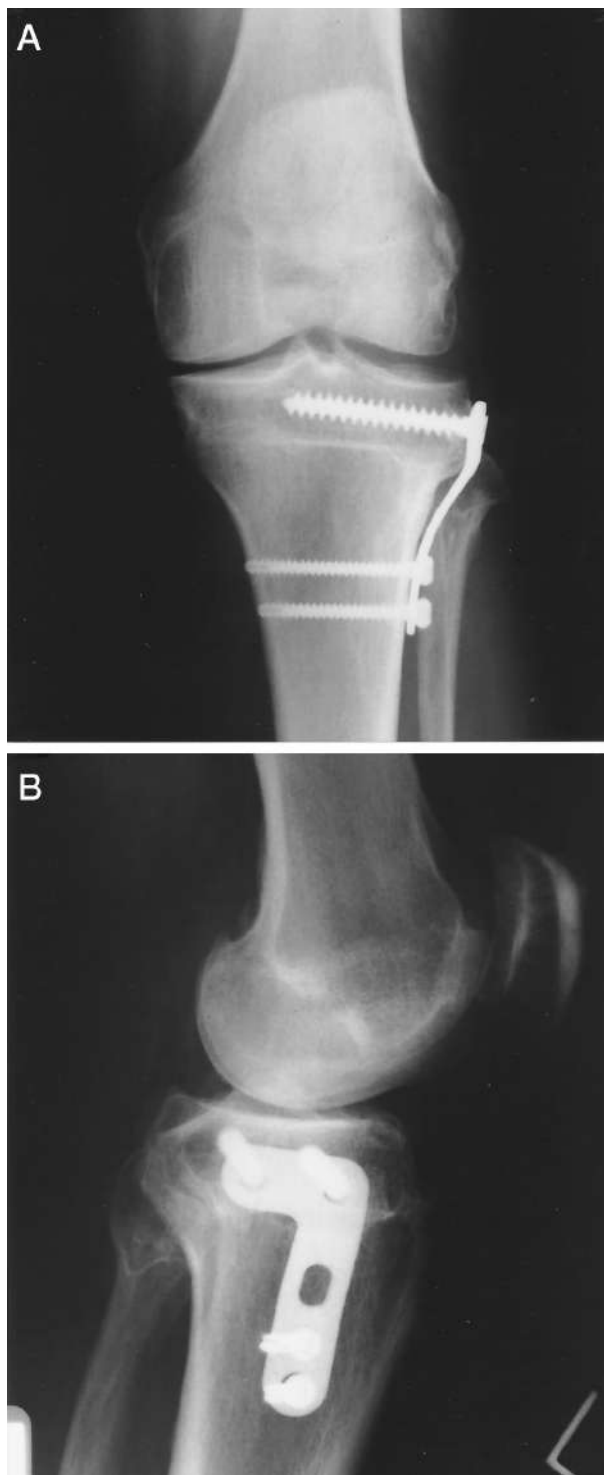


Figure 8. Anteroposterior (A) and lateral (B) radiographs show the postoperative appearance after proximal tibial osteotomy, fibular osteotomy, and internal fixation.

high knee adduction load in 10 of the 17 knees (59%). This was in agreement with our previous study on gait abnormalities in varus angulated ACL-deficient knees, in which 20 of 32 knees (63%) had a high knee adduction moment.²⁶

The high knee adduction moment is directly related to abnormally high medial compartment loads and high lateral ligament tensile forces.²⁶ Postoperatively, the abnormally high knee moments were corrected to normal or decreased to below-normal values. Other investigators have also reported significant decreases in the adduction moment after high tibial osteotomy.^{32,37}

The overall moments and forces on the knee joint are due not only to limb alignment but also to the patient's gait and dynamic forces of muscles and accelerations during ambulation. It is important to recognize that the overall limb alignment is a strong determinant of the knee adduction moment, medial tibiofemoral joint loads, and corresponding lateral ligament tensile loads. Prodromos et al.³² found no correlation between the mechanical axis of the knee and the adduction moment either pre- or postoperatively. However, Wada et al.³⁶ did find a postoperative correlation between the peak adduction moment of the knee and the tibiofemoral angle. Our results agree with those of Wada et al.; we found an increased correlation between the peak adduction moment and the mechanical axis postoperatively. However, the correlation coefficient was only moderate ($r = 0.52$), suggesting a predictive relationship in only a quarter of the patient population.

The lateral and posterolateral complex procedures used in the triple-varus knees were effective in restoring function in all but 1 of the 18 knees. One of the most important elements of obtaining a successful outcome in these procedures is an understanding of the indications for various operative techniques based on the injury and remaining integrity of the ligament tissues.¹⁷⁻¹⁹ There are three procedures to consider: proximal advancement of the entire posterolateral complex, allograft augmentation of the lateral collateral ligament and posterolateral complex, and double graft substitution using autografts for the lateral collateral ligament (bone-patellar tendon-bone) and popliteus tendon and ligament structures (semitendinosus-gracilis tendons). We have previously described the important elements of the clinical examination to detect varus recurvatum, lateral joint opening, and excessive external tibial rotation.²⁹ It is important at arthroscopy to perform the lateral joint opening gap test and measure the amount of joint opening with a calibrated nerve hook (Fig. 9). In knees that have insufficient posterolateral structures, 12 mm or more of joint opening will be measured at the periphery of the lateral tibiofemoral compartment.¹⁸ At surgery, one must also carefully inspect the lateral structures, noting the presence of scar tissue replacement, attachment site integrity, and width and size of the lateral and posterolateral structures to determine which procedure is warranted.

In knees with interstitial failure of the posterolateral tissues due to stretched out but otherwise intact attachment sites (without acute traumatic disruption), the more simplified proximal advancement may be performed. This procedure is relatively easy to perform without the added operative complexity and potential complications that occur with major graft reconstructive procedures.¹⁸ When there is more extensive damage to the posterolateral structures, such as after traumatic disruption, a major

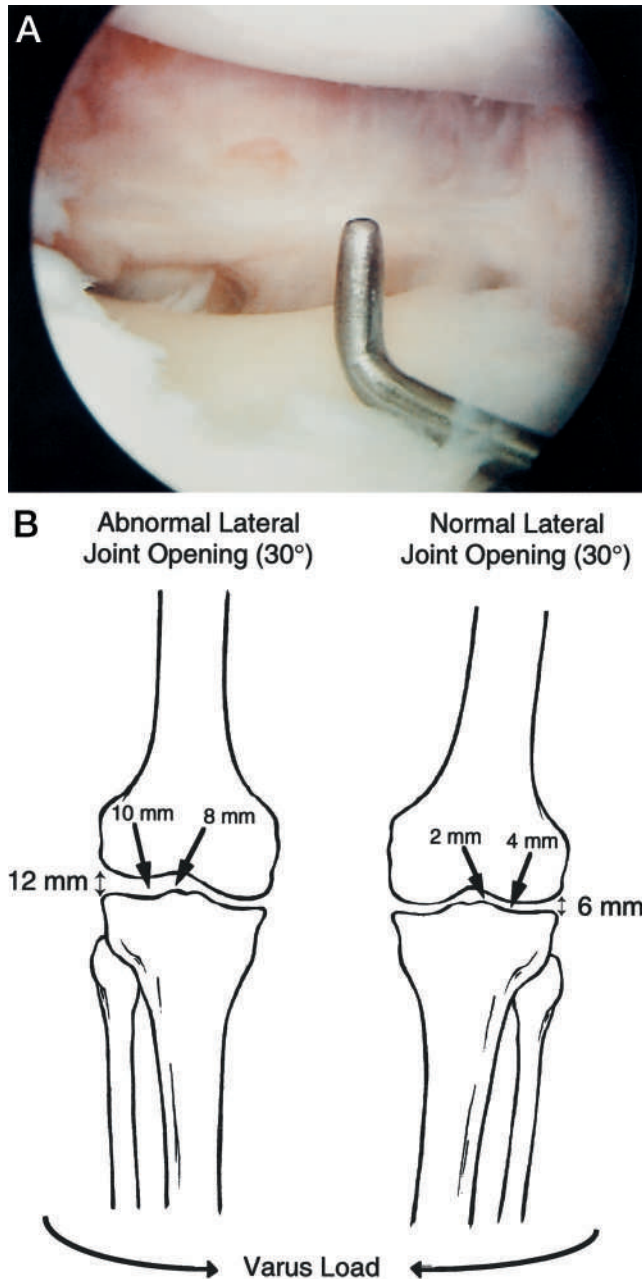


Figure 9. A, the arthroscopic gap test for determining the amount of lateral joint opening. A calibrated nerve hook is used to measure the millimeters of joint space. B, in knees that have insufficient posterolateral structures, 8 mm of lateral joint opening will be measured at the intercondylar notch, and 12 mm or more will be measured at the periphery of the lateral tibiofemoral compartment.

graft reconstruction is required.¹⁹ In the most severe cases of disruption of all the lateral and posterolateral tissues, in which inadequate collagenous tissues exist, we prefer an autogenous graft replacement of the lateral collateral ligament and posterolateral structures.¹⁷ If autogenous grafts are not available, allografts may be used.

It is important to note that only knees with complete

deficiency of the posterolateral complex (triple varus) required posterolateral ligament reconstruction. This is in contrast to double-varus knees, which had partial deficiency or increased lateral joint opening without major increases in external tibial rotation or varus recurvatum. These knees did not require posterolateral ligament reconstruction after valgus alignment was achieved. The high tibial osteotomy allowed for a physiologic remodeling and shortening of these structures.¹⁵

The timing of the osteotomy and ACL and posterolateral ligament reconstructive procedures is shown in Table 8. In the double-varus knees, the arthroscopic gap test is used as the determining factor as to whether it is safe to proceed with ACL reconstruction at the time of the osteotomy, or whether the ACL procedure should be staged to allow adaptive shortening of posterolateral tissues. An ACL reconstruction should not be done if there is concomitant excessive abnormal lateral joint opening, which would subject the ACL graft to potentially injurious forces. When a primary ACL reconstruction is performed with the osteotomy, we now prefer to use a four-bundle semitendinosus-gracilis graft to avoid using the patellar tendon and tibial bone adjacent to the osteotomy site. We believe this lessens the potential for excessive fibrosis and scar formation about the patellar tendon. In knees undergoing ACL revision reconstruction and high tibial osteotomy, we now prefer the quadriceps tendon-bone graft because prior tibial or femoral tunnels are often enlarged and a larger graft is required.

In triple-varus knees, we recommend staging the operative procedures. Performing all three procedures together results in a long procedure with an increased chance of postoperative complications, prolonged rehabilitation, and knee motion problems. We accomplish the osteotomy and then, after adequate healing, an arthroscopically assisted ACL reconstruction and open posterolateral ligament reconstruction are performed. The ACL and posterolateral ligament reconstruction must be performed together to allow both structures to function together to resist abnormal lateral joint opening and varus recurvatum.

We previously reported two prospective studies in which allografts were used in reconstructions for chronic ACL deficiency. These studies reported failure rates of 28% in primary reconstructions (32 of 115 knees)¹⁴ and 33% in revision reconstructions (25 of 75 knees).²¹ Allografts used in the initial years in the current investigation had a failure rate of 43% (10 of 23 knees). Johnson et al.¹⁰ reported a high failure rate of 36% (9 of 25 knees) in ACL allograft revision reconstructions. Because of these findings, we recommended autografts be used as the first graft choice when available. In the latter part of this study, bone-patellar tendon-bone autografts were used, which had a failure rate of 23% (5 of 22 knees). We previously reported a failure rate with bone-patellar tendon-bone autografts of 6% (3 of 53 knees) for knees with reconstruction of chronic ACL ruptures.¹⁶ We do not know if the higher failure rate for autografts in the current study represents a bias due to the small population or an actual finding due to the combined ligament instabilities and the

TABLE 8
Indications and Timing of Ligament Reconstructive Procedures

Ligament deficiency	Surgical procedure	Timing related to HTO ^a	Indications/Comments
Anterior cruciate ligament	Autograft options: 1. Central-third bone-patellar tendon-bone 2. Quadriceps tendon-patellar bone 3. Semitendinosus-gracilis tendon band	At or preferably after HTO	Any patient who had instability before HTO and who should not risk a further trial of function and possible reinjury. Consider when secondary ligament restraints are lost (pivot shift 3+ impingement, >10 mm increased anterior displacement involved knee) and associated medial or lateral ligament deficiency is present. Consider when meniscus repair is performed. Athletically active patient desiring best knee possible for return to sports activities.
Lateral collateral ligament (posterolateral complex intact, no increased external rotation or varus recurvatum)	Usually not required		Expect adaptive shortening of the LCL ^b in the majority of patients after valgus-producing osteotomy. At HTO, avoid disrupting proximal tibiofibular joint, which would allow proximal migration and laxity of posterolateral ligament structures.
Posterolateral complex, including lateral collateral ligament	1. Posterolateral complex proximal advancement 2. LCL, posterolateral complex reconstruction with autograft or allograft ^c	Staged procedure: HTO first ACL, lateral/posterolateral reconstruction	Patients usually have increased lateral joint opening of 8 mm at the intercondylar notch (12 mm or more at periphery), increased external rotation of 10° to 15°, and require posterolateral reconstruction at time of ACL reconstruction. Combined posterolateral reconstruction and ACL reconstruction always performed together to limit hyperextension and varus rotations.

^a High tibial osteotomy.

^b Lateral collateral ligament.

^c In the authors' opinion, a biceps tendon transposition is contraindicated in these knees. The biceps muscle function is required to maintain compressive forces across the lateral tibiofemoral compartment and allow active external tibial rotation. Both of these functions may be lost if the biceps tendon is transposed and fixed to the lateral femoral condyle.

high number of revision cases (7 knees, 32%). Seven of the 10 allografts that failed and 3 of the 5 autografts that failed represented knees with revision reconstructions. Certainly these results should not be compared with those of primary ACL reconstructions where no other ligament deficiencies or osseous malalignment exist.

We previously reported that not all patients with double- and triple-varus knees require or choose ACL reconstruction.¹⁵ Patients who do not undergo ACL reconstruction are counseled and warned not to return to activities that could result in giving way. Because the majority of these knees have preexisting joint arthrosis, we encourage the patient to return only to light recreational sports as long as symptoms do not occur.

SUMMARY

The patients in this investigation represented a unique group of severely affected knees that had chronic ACL deficiency, varus angulation, loss of the medial meniscus, and partial to complete posterolateral ligament insufficiency. These combined abnormalities commonly occur in younger patients who have undergone multiple operative procedures and in whom all of the abnormalities are not diagnosed or corrected. Our goal was to highlight this group of patients and stress that early correction of the varus alignment is a requirement in addition to ligament reconstruction procedures. The staged procedure ap-

proach was effective, especially in the triple-varus knees. We first corrected the varus alignment and then reconstructed the ACL and posterolateral ligaments. There were no infections, knee motion limitations, or other major complications. We hope that, in the future, with early ACL reconstruction and preservation or replacement of the medial meniscus and knowledge of the excessive loading conditions that can occur in the varus angulated knee, the sequelae of these combined injuries can be lessened or avoided.

ACKNOWLEDGMENT

This research was funded by the Cincinnati Sportsmedicine Research and Education Foundation.

REFERENCES

- Andriacchi TP, Ogle JA, Galante JO: Walking speeds as a basis for normal and abnormal gait measurements. *J Biomech* 10: 261-268, 1977
- Barber-Westin SD, Noyes FR, McCloskey JW: Rigorous statistical reliability, validity, and responsiveness testing of the Cincinnati Knee Rating System in 350 subjects with uninjured, injured, or anterior cruciate ligament-reconstructed knees. *Am J Sports Med* 27: 402-416, 1999
- Dejour H, Neyret P, Boileau P, et al: Anterior cruciate reconstruction combined with valgus tibial osteotomy. *Clin Orthop* 299: 220-228, 1994
- Dugdale TW, Noyes FR, Styer D: Preoperative planning for high tibial osteotomy: The effect of lateral tibiofemoral separation and tibiofemoral length. *Clin Orthop* 274: 248-264, 1992
- Grood ES, Stowers SF, Noyes FR: Limits of movement in the human knee: Effect of sectioning the posterior cruciate ligament and posterolateral structures. *J Bone Joint Surg* 70A: 88-97, 1988

6. Hernigou P, Medevielle D, Debeyre J, et al: Proximal tibial osteotomy for osteoarthritis with varus deformity. A ten to thirteen-year follow-up study. *J Bone Joint Surg* 69A: 332–354, 1987
7. Holden DL, James SL, Larson RL, et al: Proximal tibial osteotomy in patients who are 50 years old or less. A long-term follow-up study. *J Bone Joint Surg* 70A: 977–982, 1988
8. Hughston JC, Jacobson KE: Chronic posterolateral rotatory instability of the knee. *J Bone Joint Surg* 67A: 351–359, 1985
9. Ivarsson I, Myrneris R, Gillquist J: High tibial osteotomy for medial osteoarthritis of the knee. A 5 to 7 and 11 to 13 year follow-up. *J Bone Joint Surg* 72B: 238–244, 1990
10. Johnson DL, Swenson TM, Irrgang JJ, et al: Revision anterior cruciate ligament surgery: Experience from Pittsburgh. *Clin Orthop* 325: 100–109, 1996
11. Kettelkamp DB, Leach RE, Nasca R: Pitfalls of proximal tibial osteotomy. *Clin Orthop* 106: 232–241, 1975
12. Markolf KL, Bargar WL, Shoemaker SC, et al: The role of joint load in knee stability. *J Bone Joint Surg* 63A: 570–585, 1981
13. Morrey BF: Upper tibial osteotomy for secondary osteoarthritis of the knee. *J Bone Joint Surg* 71B: 554–559, 1989
14. Noyes FR, Barber SD: The effect of a ligament-augmentation device on allograft reconstructions for chronic ruptures of the anterior cruciate ligament. *J Bone Joint Surg* 74A: 960–973, 1992
15. Noyes FR, Barber SD, Simon R: High tibial osteotomy and ligament reconstruction in varus angulated, anterior cruciate ligament-deficient knees. A two- to seven-year follow-up study. *Am J Sports Med* 21: 2–12, 1993
16. Noyes FR, Barber-Westin SD: A comparison of results in acute and chronic anterior cruciate ligament ruptures of arthroscopically assisted autogenous patellar tendon reconstruction. *Am J Sports Med* 25: 460–471, 1997
17. Noyes FR, Barber-Westin SD: Treatment of complex injuries involving the posterior cruciate and posterolateral ligaments of the knee. *Am J Knee Surg* 9: 200–214, 1996
18. Noyes FR, Barber-Westin SD: Surgical restoration to treat chronic deficiency of the posterolateral complex and cruciate ligaments of the knee joint. *Am J Sports Med* 24: 415–426, 1996
19. Noyes FR, Barber-Westin SD: Surgical reconstruction of severe chronic posterolateral complex injuries of the knee using allograft tissues. *Am J Sports Med* 23: 2–12, 1995
20. Noyes FR, Barber-Westin SD, Butler DL, et al: The role of allografts in repair and reconstruction of knee joint ligaments and menisci. *Instr Course Lect* 47: 379–396, 1998
21. Noyes FR, Barber-Westin SD, Roberts CS: Use of allografts after failed treatment of rupture of the anterior cruciate ligament. *J Bone Joint Surg* 76A: 1019–1031, 1994
22. Noyes FR, Cummings JF, Grood ES, et al: The diagnosis of knee motion limits, subluxations, and ligament injury. *Am J Sports Med* 19: 163–171, 1991
23. Noyes FR, Dunworth LA, Andriacchi TP, et al: Knee hyperextension gait abnormalities in unstable knees. Recognition and preoperative gait retraining. *Am J Sports Med* 24: 35–45, 1996
24. Noyes FR, Moar PA, Matthews DS, et al: The symptomatic anterior cruciate-deficient knee. Part I: The long-term functional disability in athletically active individuals. *J Bone Joint Surg* 65A: 154–162, 1983
25. Noyes FR, Roberts CS: High tibial osteotomy in knees with associated chronic ligament deficiencies, in Jackson DW (ed): *Master Techniques in Orthopaedic Surgery. Reconstructive Knee Surgery*. New York, Raven Press, 1995, pp 185–210
26. Noyes FR, Schipplein OD, Andriacchi TP, et al: The anterior cruciate ligament-deficient knee with varus alignment. An analysis of gait adaptations and dynamic joint loadings. *Am J Sports Med* 20: 707–716, 1992
27. Noyes FR, Simon R: The role of high tibial osteotomy in the anterior cruciate ligament-deficient knee with varus alignment, in DeLee JC, Drez D (eds): *Orthopaedic Sports Medicine. Principles and Practice*. Philadelphia, WB Saunders, 1994, pp 1401–1443
28. Noyes FR, Stabler CL: A system for grading articular cartilage lesions at arthroscopy. *Am J Sports Med* 17: 505–513, 1989
29. Noyes FR, Stowers SF, Grood ES, et al: Posterior subluxations of the medial and lateral tibiofemoral compartments. An in vitro ligament sectioning study in cadaveric knees. *Am J Sports Med* 21: 407–414, 1993
30. Odenbring S, Tjörnstrand B, Egund N, et al: Function after tibial osteotomy for medial gonarthrosis below aged 50 years. *Acta Orthop Scand* 60: 527–531, 1989
31. Perry J (ed): *Gait Analysis: Normal and Pathological Function*. Thorofare, NJ, Slack, Inc, 1992, pp 49–281
32. Prodromos CC, Andriacchi TP, Galante JO: A relationship between gait and clinical changes following high tibial osteotomy. *J Bone Joint Surg* 67A: 1188–1194, 1985
33. Rosenberg TD, Paulos LE, Parker RD, et al: The forty-five-degree posteroanterior flexion weight-bearing radiograph of the knee. *J Bone Joint Surg* 70A: 1479–1483, 1988
34. Rubman MH, Noyes FR: Varus angulation with chronic ligament deficiency: The role of high tibial osteotomy, in Craig EV (ed): *Clinical Orthopaedics*. Philadelphia, Lippincott Williams & Wilkins, 1999, pp 783–792
35. Schipplein OD, Andriacchi TP: Interaction between active and passive knee stabilizers during level walking. *J Orthop Res* 9: 113–119, 1991
36. Wada M, Imura S, Nagatani K, et al: Relationship between gait and clinical results after high tibial osteotomy. *Clin Orthop* 354: 180–188, 1998
37. Wang JW, Kuo KN, Andriacchi TP, et al: The influence of walking mechanics and time on the results of proximal tibial osteotomy. *J Bone Joint Surg* 72A: 905–909, 1990
38. Wroble RR, Van Ginkel LA, Grood ES, et al: Repeatability of the KT-1000 arthrometer in a normal population. *Am J Sports Med* 18: 396–399, 1990