

## Surgical Technique

### Development of an Anatomic Medial Knee Reconstruction

Robert F. LaPrade MD, PhD, Coen A. Wijdicks PhD

Published online: 10 September 2011  
© The Association of Bone and Joint Surgeons® 2011

#### Abstract

**Background** The main static stabilizers of the medial knee are the superficial medial collateral and posterior oblique ligaments. A number of reconstructive techniques have been advocated including one we describe here. However, whether these reconstructions restore function and stability is unclear.

**Description of Technique** This anatomic reconstruction technique consisted of reconstruction of the proximal and distal divisions of the superficial medial collateral and the posterior oblique ligament using two separate grafts.

**Patients and Methods** We prospectively followed all 28 patients (19 male, nine females) who had this new reconstruction between 2007 and 2009. The average age was 32.4 years (range, 16–56 years). There were eight acute and 20 chronic injuries. All patients presented with side-to-side instability with activities of daily living and other higher level activities. Minimum followup was 6 months (average, 1.5 years; range, 0.5–3 years). No patients were lost to followup.

**Results** Preoperative International Knee Documentation Committee subjective outcome scores averaged 43.5 (range, 14–66) and final postoperative values averaged

76.2 (range, 54–88). Preoperative valgus stress radiographs averaged 6.2 mm of medial compartment gapping compared with the contralateral normal knee, whereas postoperative stress radiographs averaged 1.3 mm.

**Conclusions** Early observations suggest this anatomic reconstruction technique improves overall patient function and restores valgus instability.

#### Introduction

Due to the intricate relationships among the superficial medial collateral ligament and other medial knee stabilizers, ie, the deep medial collateral ligament and the posterior oblique ligament, an injury to the medial knee structures should not be identified solely as a “medial collateral ligament” injury. Because these injuries are so common, it has not been unusual in the senior partner’s (RFL) practice to have patients referred to him with chronic isolated posterolateral corner injuries who were in fact misdiagnosed with medial knee injuries and who had major functional limitations, especially with side-to-side instability. Thus, we established a collaborative project with the University of Oslo to develop an anatomic medial knee reconstruction technique to better restore the static function and overall stability to these patients and to allow immediate postoperative knee motion to decrease the risk of the postoperative stiffness issues commonly seen with medial knee surgeries [11]. This involved detailed quantitative anatomic studies [9], static biomechanical sectioning studies [5], assessment of forces in the native medial knee structures to applied loads [4, 15], and the development and biomechanical validation of an anatomic medial knee reconstruction technique [3].

---

One or more of the authors (RFL, CAW) received funding from the Research Council of Norway (Grant 175047/D15) and Health East Norway (Grant 10703604).

Each author certifies that his or her institution approved the human protocol for this investigation, that all investigations were conducted in conformity with ethical principles of research, and that informed consent for participation in the study was obtained.

---

R. F. LaPrade (✉), C. A. Wijdicks  
Steadman Philippon Research Institute, The Steadman Clinic,  
181 West Meadow Drive, Suite 400, Vail, CO 81657, USA  
e-mail: drlaprade@sprvail.org

The three main structures that provide stability to the medial knee are the superficial medial collateral ligament, posterior oblique ligament, and deep medial collateral ligament. These three structures work together to provide both primary and secondary static stabilization roles for valgus, external rotation, and internal rotation stability to the knee. As part of the development and optimization of an anatomic medial knee reconstruction technique, we performed biomechanical studies that included static sectioning studies of the posterior oblique ligament, proximal and distal divisions of the superficial medial collateral ligament, and meniscofemoral and meniscotibial divisions of the deep medial collateral ligament [4] and measurement of the forces present on the proximal and distal divisions of the superficial medial collateral ligament and the posterior oblique ligament to applied loads in both the intact [5] and sectioned states [14]. The anatomic information was utilized to develop the locations of the medial knee reconstruction grafts and to place them into anatomic locations, while the biomechanical studies provided important information about the static stability and load-sharing functions of each individual component of the medial knee structures. Biomechanical testing of our anatomic reconstruction technique then confirmed the reconstruction grafts restored stability to the medial knee and the reconstruction grafts had load sharing similar to that of the native medial knee structures, which indicated they were not being overconstrained [3] (Appendix 1).

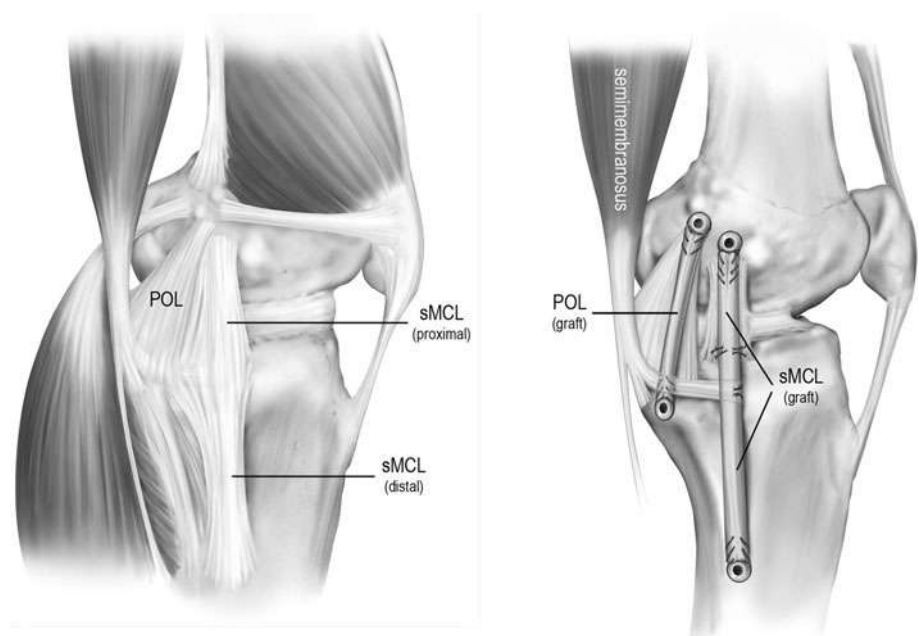
We describe a new anatomic medial knee reconstruction technique based on quantitative anatomy and report our preliminary findings on knee function and restoration of stability in patients who had this new reconstruction.

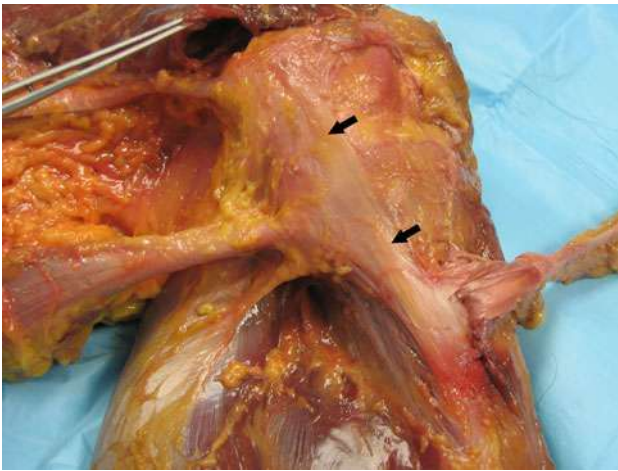
## Surgical Technique

This anatomic reconstruction technique consisted of a reconstruction of the proximal and distal divisions of the superficial medial collateral and the posterior oblique ligament using two separate grafts (Fig. 1). (Appendix 1 illustrates details about the quantitative locations and surgically important landmarks for identification of the individual structure attachment sites for optimal location of the reconstruction tunnels.) First, an anteromedial incision was made along the medial knee, initiating from 4 cm medial to the patella and extending distally over the mid-portion of the tibia approximately 7 to 8 cm distal to the joint line.

To expose the distal tibial attachment site of the superficial medial collateral ligament, the fascial expansion of the sartorius muscle was incised and the gracilis and semitendinosus tendons were exposed. Deep within the pes anserine bursa, the distal tibial attachment of the superficial medial collateral ligament was identified (Fig. 2). In all circumstances, we verified this attachment site was 6 cm distal to the joint line. We also verified this reconstruction tunnel was placed at the posterior aspect of this attachment site, rather than the anterior aspect, because we found during our pilot testing, when the distal tibial reconstruction tunnel was placed slightly anterior, all of the reconstruction grafts failed during biomechanical testing. At this point, an eyelet passing pin was drilled through the center of the distal attachment site and transversely across the tibia. A 7-mm reamer was then reamed to a depth of 25 mm. In smaller patients, consideration may be given to reaming 6-mm tunnels for the

**Fig. 1** A diagram of a right knee illustrates the superficial medial collateral ligament (sMCL) and posterior oblique ligament (POL) reconstruction grafts. Reprinted with permission of SAGE Publications, Inc, from Coobs BR, Wijdicks CA, Armitage BM, Spiridonov SI, Westerhaus BD, Johansen S, Engebretsen L, LaPrade RF. An in vitro analysis of an anatomic medial knee reconstruction. *Am J Sports Med.* 2010;38:339–347. Copyright © 2009, American Orthopaedic Society for Sports Medicine.

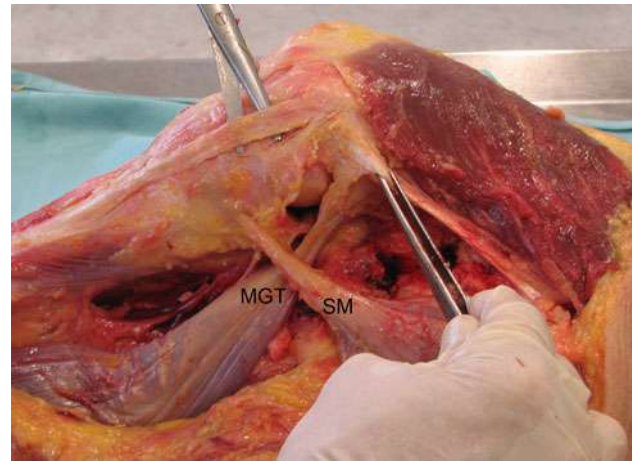




**Fig. 2** A photograph of a left knee demonstrates the course of the superficial medial collateral ligament (arrows).

reconstruction, but our reconstruction was only validated using 7-mm reconstruction grafts [3]. After the reconstruction tunnel was prepared, we then turned our attention to identification of the posterior oblique ligament tibial reconstruction tunnel. The attachment site of the central arm of the posterior oblique ligament was identified at the posteromedial tibia, just slightly anterior to the direct arm attachment of the semimembranosus tendon. Exposure of this attachment site was performed through a small incision parallel to the fibers of the posterior edge of the anterior arm of the semimembranosus tendon. Once this was identified, an eyelet passing pin was similarly drilled across the tibia toward Gerdy's tubercle. Once it was verified this eyelet pin was in the correct anatomic location, a 7-mm reamer drilled the tunnel to a depth of 25 mm.

The attachment locations of the superficial medial collateral ligament and posterior oblique ligament on the femur were next identified (Fig. 3). In some circumstances, intraoperative fluoroscopy may be required to assist with identification of the correct femoral attachment sites [14]. To best identify these landmarks, we recommend isolation of the distal attachment of the adductor magnus tendon initially. The bony prominence slightly distal to its attachment is the adductor tubercle. One can then identify the medial epicondyle by visualizing the bony prominence distal to this and almost parallel to the shaft of the femur. On average, the medial epicondyle is 12.6 mm distal and 8.3 mm anterior to the adductor tubercle. The attachment site of the superficial medial collateral ligament is slightly proximal and anterior to this location. Once this site was identified, an eyelet passing pin was drilled transversely across the femur. It is not recommended to ream this tunnel until the attachment site of the posterior oblique ligament has been definitively identified.

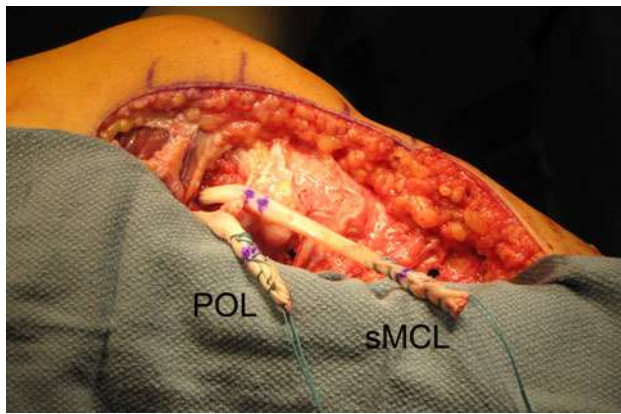


**Fig. 3** A photograph of a right knee demonstrates the relationships between the femoral attachments of the superficial medial collateral ligament (scissors deep to superficial medial collateral ligament), the posterior oblique ligament, and the adductor magnus tendon (in forceps). SM = semimembranosus; MGT = medial gastrocnemius tendon.

The next surgical step was to identify the posterior oblique ligament femoral attachment. If the entire posteromedial capsule was torn off the femur, we identified the medial gastrocnemius tendon, followed it to its femoral attachment site, and then identified the gastrocnemius tubercle by its adjacent nature to this attachment site. On average, the gastrocnemius tubercle is 2.6 mm distal and 3.1 mm anterior to the medial gastrocnemius tendon femoral attachment. The posterior oblique ligament femoral attachment is 7.7 mm distal and 2.9 mm anterior to the gastrocnemius tubercle. If the posteromedial capsule was still intact, a small incision posterior to the remnants of the superficial medial collateral ligament, vertical and into the joint, was placed to identify the femoral attachment site of the central arm of the posterior oblique ligament. An eyelet passing pin was then similarly drilled across the femur. Once this was done, a 7-mm reamer drilled each reconstruction tunnel to a depth of 25 mm. It is recommended to not separately ream these tunnels before verification of the attachment sites of both structures because of the potential of having a tunnel not located in the ideal location.

We found the reconstruction grafts for the superficial medial collateral ligament should be 16 cm in length, whereas those for the posterior oblique ligament should be 12 cm in length. Although these reconstruction graft lengths may need to be changed in very small or much larger patients, we have found they have fit the requirements both for our in vivo and in vitro reconstructions and consistently allowed for a minimum of 25 mm of graft to be placed within the reconstruction tunnels.

The superficial medial collateral ligament and posterior oblique ligament grafts were then pulled into their



**Fig. 4** A photograph of a left knee demonstrates the posterior oblique ligament (POL) and superficial medial collateral ligament (sMCL) grafts passed into their femoral tunnels.

respective tunnels. A cannulated bioabsorbable screw was then inserted to secure the reconstruction grafts into their positions (Fig. 4).

The two reconstruction grafts were then passed distally. We passed the posterior oblique ligament graft distally within the substance of the native posterior oblique ligament and then into its tibial reconstruction tunnel. The superficial medial collateral ligament graft was likewise placed under the sartorius fascia and any remnants of the superficial medial collateral ligament and then passed into its tibial tunnel using an eyelet passing pin. Once any concurrent cruciate ligament reconstruction grafts were stabilized in their tunnels, attention was turned toward securing the medial knee reconstruction grafts in their tibial tunnels.

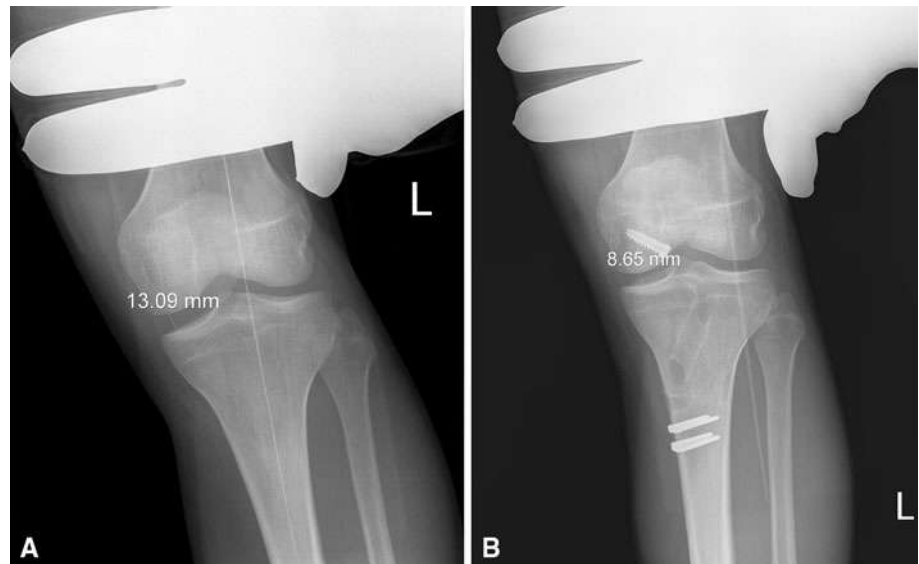
First, the posterior oblique ligament graft was tightened in full extension. Once the posterior oblique ligament graft was fixed in its tibial tunnel, the superficial medial collateral ligament graft was then fixed in its tibial tunnel. The graft should be fixed with the tibia in neutral rotation, at 20° of knee flexion, and a slight varus reduction force to verify no medial compartment gapping occurs. Once this was done, we turned our attention to fixing the proximal tibial attachment site of the superficial medial collateral ligament graft. This attachment averages 12.2 mm distal to the medial joint line and is directly medial to the anterior arm of the semimembranosus tibial attachment. A suture anchor was placed at this location and the graft was secured at this site, which restored the native proximal tibial attachment of the superficial medial collateral ligament. The strength of the suture anchor reconstruction graft fixation was reportedly comparable to that of the native strength of the proximal division attachment on the tibia [12]. At this point, the knee was flexed to the point where it appeared any concurrent repaired tissues could be maximally flexed to determine the “safe zone” ROM, which could be initiated on Postoperative Day 1.

The following rehabilitation guidelines are based on peer-reviewed published Level 5 guidelines [13]. Early ROM was stressed for an anatomic medial knee reconstruction so that intraarticular adhesions and quadriceps atrophy did not develop. Ideally, patients initiated physical therapy the day after their medial knee reconstruction and worked within the “safe zone” determined intraoperatively as the amount of motion that can be performed within the first 2 weeks after surgery. In addition, patients performed frequent quadriceps setting exercises and patella mobilizations. It is also recommended patients be non-weightbearing for their first 6 weeks to maximize healing of their reconstruction grafts. It is essential aggressive ROM exercises in which a therapist maximally stresses the knee out of the “safe zone” not be performed for the first 2 weeks postoperatively and these patients work with their physical therapist on passive motion to ensure the reconstruction grafts do not stretch out. Patients also performed quadriceps setting exercises, straight-leg raises in the brace until they could perform them without an extension sag, and hip extension and abduction exercises during this time frame. After the initial 2 weeks postoperatively, further knee flexion was allowed to increase to full ROM as tolerated.

Weightbearing exercises were initiated at 6 weeks postoperatively. When gait training is initiated, it is important to educate the patients about avoiding pivoting motions of their foot while participating in activities, which could stress the reconstruction grafts at the knee. Closed-kinetic-chain exercises were permitted for functional strengthening with the addition of two-limb support squatting. Ideally, we limited leg presses to 70° of knee flexion to minimize excessive joint translation during this time frame because, after 70° of knee flexion, the cam shape of the posterior aspect of the femoral condyles starts to initiate posterior translation forces at the knee. It is also important for the therapists to stress good judgment for the patients to avoid substantial tibial internal or external rotation for the first few months after the medial knee reconstruction. After the initiation of weightbearing, we stressed restoration of normal gait mechanics. With initiation of weightbearing, it is important to not excessively stress the joint such that knee effusions develop due to overuse activities while there is quadriceps and lower extremity weakness present. Knee effusions could affect quadriceps function and result in a quadriceps avoidance gait pattern with a hyperextension thrust during the stance phase.

Once the patient was able to walk without a substantial limp, further lower-extremity strength training and proprioception exercises were initiated. This was usually at the 16- to 20-week point postoperatively, depending on whether the patient had an isolated or concurrent

**Fig. 5A–B** (A) Preoperative and (B) 2-year postoperative valgus stress radiographs of a left knee after an anatomic medial knee reconstruction are shown.



multiple-ligament combined medial knee reconstruction. Return to sports and full activities were based on passing activity-specific functional tests and demonstrating objective evidence of healing on valgus stress radiographs [8] (Fig. 5).

### Patients and Methods

We prospectively followed all 28 patients (19 males, nine females) who had this new reconstruction. The average age was 32.4 years (range, 16–56 years) (Table 1). There were eight acute and 20 chronic injuries. All patients presented with side-to-side instability with activities of daily living and other higher-level activities. The indications for surgery were an acute medial knee injury with a midsubstance nonrepairable tear of the superficial medial collateral ligament and posterior oblique ligament. Indications for a chronic medial knee reconstruction included symptomatic side-to-side instability with evidence of increased valgus gapping compared with the contralateral knee and an increase in external rotation on the dial and anteromedial drawer tests. The contraindications for surgery were acute repairable tears of the medial knee structures or any ongoing active infection. Exclusion criteria for this study also included patients who had bilateral knee injuries or a history of a medial knee injury on the contralateral side. Minimum followup was 6 months (average, 1.5 years; range, 0.5–3 years). No patients were lost to followup.

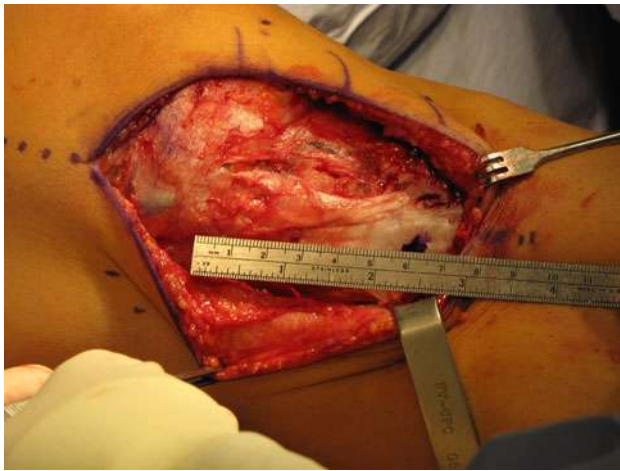
Upon enrollment in the study, all patients were instructed to followup for an objective and subjective assessment at 6 months, 1 year, and 2 years postoperatively. Followup clinical examination included assessment of a patient's valgus and varus stability in full extension

**Table 1.** Demographics and results of an anatomic medial knee reconstruction

Variable	Value
Age (years)*	32.4 (16–56)
Male:female	19:9
Acute:chronic	8:20
Isolated:combined	2:26
Surgery	
ACL/medial knee structures	8
PCL/medial knee structures	9
ACL/PCL/medial knee structures	9
Mechanism of injury	
Valgus contact	7
Twist	5
Fall	9
Motor vehicle accident	7
Followup (years)*	1.5 (0.5–3)
Preoperative valgus stress radiographs (mm)*	6.2 (3.5–14)
Postoperative valgus stress radiographs (mm)*	1.3 (–1.0–2.0)
Preoperative IKDC subjective outcome scores*	43.5 (14–65)
Postoperative IKDC subjective outcome scores*	76.2 (54–88)

\* Values are expressed as mean, with range in parentheses; IKDC = International Knee Documentation Committee.

and at 20° of knee flexion, the Lachman and pivot shift, posterior drawer test, anteromedial and posterolateral drawer tests, the dial test, and the reverse pivot shift of both knees. All patients completed International Knee Documentation Committee (IKDC) [1, 6] subjective outcome scores both at initial presentation and at final followup evaluation. All patients had preoperative valgus stress radiographs and followup objective examinations including valgus stress radiographs at 6, 12, and 24 months



**Fig. 6** An intraoperative photograph demonstrates the 6-cm distance between the medial joint line and the distal superficial medial collateral ligament attachment (left knee).

postoperatively to objectively determine the increase in side-to-side instability compared with the contralateral normal knee. All stress radiographs were performed by the senior author (RFL) according to previously published techniques, which are associated with high interobserver and intraobserver repeatability and with clinician-applied forces similar to measured forces [8].

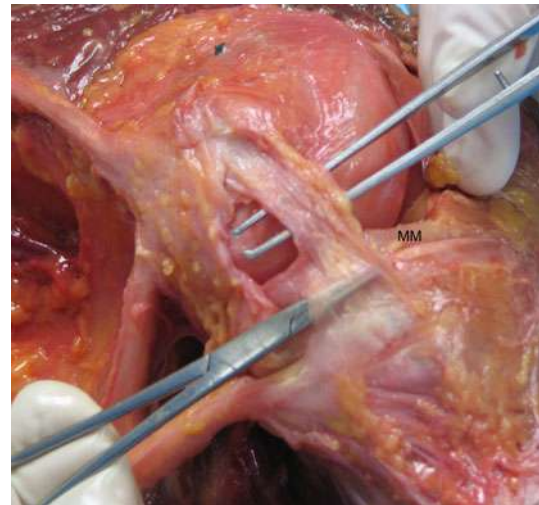
## Results

Preoperative IKDC subjective outcome scores averaged 43.5 (range, 14–65), whereas final postoperative values averaged 76.2 (range, 54–88). All patients noted resolution of side-to-side instability symptoms at the time of final followup. Preoperative bilateral valgus stress radiographs averaged 6.2 mm (range, 3.5–14 mm) of medial compartment gapping compared with the contralateral normal knee, whereas postoperative stress radiographs averaged 1.3 mm (range, –1.0 to 2 mm) of increased gapping compared to the normal contralateral knee.

No patient had recurrent laxity of the medial knee reconstruction or any of the concurrent cruciate ligament reconstructions. One patient had a postoperative wound infection at 12 weeks postoperatively, which required irrigation and débridement. This healed without further sequelae. There were no further reoperations or complications in this series.

## Discussion

We believed a new medial knee reconstruction technique was important to provide a more anatomic knee



**Fig. 7** A photograph of a left knee demonstrates the meniscofemoral and meniscotibial divisions of the deep medial collateral ligament. Superficial medial collateral ligament and posterior oblique were removed. MM = medial meniscus.

reconstruction and allow earlier knee ROM. Because the majority of previously described techniques are more sling-type procedures [2, 7, 10] and do not reproduce the native anatomy of the medial knee, the ability to initiate early knee motion is compromised. Similar to the reconstruction history of the cruciate ligaments and the posterolateral aspect of the knee, over time, surgeons have strived to develop more anatomic reconstructions over sling procedures due to improved outcomes with more objective measurement techniques. We describe a new anatomic medial knee reconstruction technique based on quantitative anatomy and report our preliminary findings on knee function and restoration of stability in patients who had this new reconstruction.

Our study is limited by a number of factors. First, the average followup is short and further long-term followup is necessary to ensure instability does not recur over time. Second, the majority of the surgical procedures are not for isolated medial knee reconstructions. However, it is recognized the majority of Grade III isolated medial knee reconstructions do heal and this cohort appears to agree with that point. Finally, this surgical technique was performed solely by its developers and further verification of these results by other centers is recommended.

We found this anatomic medial knee reconstruction of the main medial knee static stabilizers restored valgus, external rotation, and internal rotation stability to a knee with objective evidence of instability from a Grade III acute or chronic medial knee injury. In the face of severe acute and chronic medial knee instability, we recommend considering an anatomic reconstruction of the superficial medial collateral ligament and the posterior oblique

ligament. Preliminary subjective and objective results suggest restoration of stability and function, although long-term followup is required to ensure these are maintained.

**Acknowledgments** We thank Lars Engebretsen, MD, PhD, Benjamin Coobs MD, and Steinar Johansen, MD, for their assistance with the anatomic and biomechanical studies leading up to this surgical technique.

## Appendix 1

### Medial Knee Anatomic Structures

The three main structures that provide stability to the medial knee are the superficial medial collateral ligament, posterior oblique ligament, and deep medial collateral ligament. These three structures work together to provide both primary and secondary static stabilization roles for valgus, external rotation, and internal rotation stability to the knee.

The superficial medial collateral ligament is the most important structure on the medial aspect of the knee. It averages 9.5 cm in length and has one femoral and two tibial attachments. The femoral attachment site is 3.2 mm proximal and 4.8 mm posterior to the medial epicondyle [9]. It is important to recognize this femoral attachment is not to the medial epicondyle, as has been noted in some older anatomy textbooks. It is from this femoral attachment site that the superficial medial collateral ligament then courses distally to two tibial attachments. The more proximal tibial attachment site is approximately 1.2 cm distal to the joint line. This attachment site is primarily to soft tissues, with the main soft tissue structure it is attached to being the anterior arm of the semimembranosus [9]. From this location, the majority of its fibers course distally to attach to bone approximately 6 cm distal to the tibial surface. In our studies, we have found, in almost all patients, no matter their size, the distal tibial attachment site of the superficial medial collateral ligament was 6 cm distal to the joint line (Fig. 6). We have found this to be an important landmark to use intraoperatively, especially for a chronic medial knee injury.

The posterior oblique ligament is also an important medial knee stabilizer. This structure has several attachments at the knee, with the most important being the central arm [9]. The posterior oblique ligament is a reinforcement of the posteromedial joint capsule, which courses off the semimembranosus tendon. It is located posterior to the superficial medial collateral ligament and is not able to be separated away from the joint capsule. The posterior oblique ligament is basically a thickening of the fibers of the posteromedial joint capsule, with the attachment site on the femur 7.7 mm distal and 2.9 mm anterior

to the gastrocnemius tubercle. In the past, the gastrocnemius tubercle was not well recognized, and the anatomic literature was variable about descriptions of the attachment site of the posterior oblique ligament. In fact, most references referred it to attaching close to or at the adductor tubercle, which has now been proven inaccurate [9].

The deep medial collateral ligament is the other main medial knee anatomic structure. The deep medial collateral ligament is a thickening of the medial joint capsule and is primarily deep to the superficial medial collateral ligament. Its attachment site on the femur is 12.6 mm distal to the superficial medial collateral ligament's attachment site, whereas its attachment site on the tibia is 3.2 mm distal to the articular surface of the tibia. It has a stout attachment to the medial meniscus. Thus, it is commonly divided into meniscofemoral and meniscotibial divisions (Fig. 7).

### Clinically Relevant Biomechanics Studies on the Medial Knee

As part of the development of an anatomic medial knee reconstruction technique, we measured the forces present on the proximal and distal divisions of the superficial medial collateral ligament and the posterior oblique ligament to applied loads [5, 13]. We believed it was important to perform this analysis so we could determine whether these loads could be duplicated in an anatomic reconstruction technique such that overconstraint of the reconstruction grafts would not occur. In this study, we found external rotation torques produced considerably higher loads on the distal division of the superficial medial collateral ligament than internal rotation torques with increasing knee flexion angles. In addition, the role of the posterior oblique ligament in preventing valgus was found to be most important in full extension. Also, with the knee in full extension, the load response for internal rotation on the posterior oblique ligament was substantially higher than that seen on both divisions of the superficial medial collateral ligament, whereas at 90° of knee flexion, the load response to internal rotation torques was substantially higher on the distal division of the superficial medial collateral ligament than on the posterior oblique ligament. Thus, we found important new knowledge about the individual biomechanical function and load sharing between these important medial knee structures. Importantly, we found the superficial medial collateral ligament was essentially comprised of two separate divisions, with the proximal division being more important to valgus stability and the distal division more important to providing external rotation stability to the knee [4, 5, 13].

Concurrent with this force measurement study, we also performed a static sectioning study of the posterior oblique

ligament, proximal and distal divisions of the superficial medial collateral ligament, and meniscotibial and meniscotibial divisions of the deep medial collateral ligament in 24 cadaveric knees [4]. The cadavers were divided into three separate groups with unique cutting sequences. Through this study, we identified the primary stabilizer to valgus was the proximal division of the superficial medial collateral ligament. In addition, we found the primary external rotation stabilizer of the medial knee was the distal division of the superficial medial collateral ligament at 30° of knee flexion. The posterior oblique ligament and the distal division of the superficial medial collateral ligament were also important primary internal rotation stabilizers. In addition, we found there was as much external rotation at 30° of knee flexion with the medial knee structures sectioned as had been reported with a posterolateral corner injury [4]. In addition, we found an increased amount of external rotation was present at 90° for an isolated medial knee injury. Thus, we identified that the medial knee structures have an important role in external rotation stability and clinical interpretation of the dial test should be carefully assessed to determine whether the instability is the result of either a posterolateral or a medial knee injury.

After these biomechanical force measurement and static cutting studies were completed, we then performed a series of pilot studies attempting to develop an anatomically based medial knee reconstruction of the superficial medial collateral ligament and the posterior oblique ligament. We piloted nine different reconstruction techniques as part of our attempts to determine the ideal reconstruction technique to both provide postoperative stability and not overload the reconstruction grafts. One important finding was that all our pilot knees that had one femoral tunnel failed during biomechanical testing. Although this may not condemn all reconstruction techniques with one femoral tunnel for these structures, it did reveal we would not be able to initiate an early ROM program, which was strongly desired, as part of our medial knee reconstruction technique if we only used one femoral reconstruction tunnel. We also found, to prevent reconstruction graft overload, the posterior oblique ligament graft needed to be fixed in extension, whereas the superficial medial collateral ligament graft was required to be secured at 20° of knee flexion. Once our anatomic technique had been devised, we then performed biomechanical testing of 10 nonpaired cadaveric knees. They were tested in the intact, sectioned, and reconstructed states. Buckle transducers measured the loads on the intact and reconstructed proximal and distal divisions of the superficial medial collateral ligament and the posterior oblique ligament to verify there was no substantial graft overload. In this reconstruction technique, we were able to restore the native stability to the knee while at the same time there were no clinically important

differences between the observed load on these ligaments when comparing the intact with the reconstructed states for valgus, external rotation, and internal rotation and AP loads. Thus, we found this anatomic medial knee reconstruction technique restored near-normal stability to a knee with complete superficial medial collateral ligament and posterior oblique ligament injuries and, at the same time, avoided overconstraint of the reconstructed ligament grafts.

## References

1. Agel J, LaPrade RF. Assessment of differences between the Modified Cincinnati and International Knee Documentation Committee Patient outcome scores: a prospective study. *Am J Sports Med.* 2009;37:2151–2157.
2. Bosworth DM. Transplantation of the semitendinosus for repair of laceration of medial collateral ligament of the knee. *J Bone Joint Surg Am.* 1952;34:196–202.
3. Coobs BR, Wijdicks CA, Armitage BM, Spiridonov SI, Westerhaus BD, Johansen S, Engebretsen L, LaPrade RF. An in vitro analysis of an anatomic medial knee reconstruction. *Am J Sports Med.* 2010;38:339–347.
4. Griffith CJ, LaPrade RF, Johansen S, Armitage B, Wijdicks C, Engebretsen L. Medial knee injury. Part 1. Static function of the individual components of the main medial knee structures. *Am J Sports Med.* 2009;37:1762–1770.
5. Griffith CJ, Wijdicks CA, LaPrade RF, Armitage BM, Johansen S, Engebretsen L. Force measurements on the posterior oblique ligament and superficial medial collateral ligament proximal and distal divisions to applied loads. *Am J Sports Med.* 2009;37:140–148.
6. Hefti F, Muller W, Jakob RP, Stabubli HU. Evaluation of knee ligament injuries with the IKDC form. *Knee Surg Sports Traumatol Arthrosc.* 1993;1:226.
7. Kim SJ, Lee DH, Kim TE, Choi NH. Concomitant reconstruction of the medial collateral and posterior oblique ligaments for medial instability of the knee. *J Bone Joint Surg Br.* 2008;90:1323–1327.
8. LaPrade RF, Bernhardson AS, Griffith CJ, Macalena JA, Wijdicks CA. Correlation of valgus stress radiographs with medial knee ligament injuries: an in vitro biomechanical study. *Am J Sports Med.* 2010;38:330–338.
9. LaPrade RF, Engebretsen AH, Ly TV, Johansen S, Wentorf FA, Engebretsen L. The anatomy of the medial part of the knee. *J Bone Joint Surg Am.* 2007;89:2000–2010.
10. Lind M, Jakobsen BW, Lund B, Hansen MS, Abdallah O, Christiansen SE. Anatomical reconstruction of the medial collateral ligament and posteromedial corner of the knee in patients with chronic medial collateral ligament instability. *Am J Sports Med.* 2009;37:1116–1122.
11. Miyamoto RG, Bosco JA, Sherman OH. Treatment of medial collateral ligament injuries. *J Am Acad Orthop Surg.* 2009;17:152–161.
12. Wijdicks CA, Brand EJ, Nuckley DJ, Johansen S, LaPrade RF, Engebretsen L. Biomechanical evaluation of a medial knee reconstruction with comparison of bioabsorbable interference screw constructs and optimization with a cortical button. *Knee Surg Sports Traumatol Arthrosc.* 2010;18:1532–1541.
13. Wijdicks CA, Griffith CJ, Johansen S, Engebretsen L, LaPrade RF. Injuries to the medial collateral ligament and associated medial structures of the knee. *J Bone Joint Surg Am.* 2010;92:1266–1280.



14. Wijdicks CA, Griffith CJ, LaPrade RF, Johansen S, Sunderland A, Arendt EA, Engebretsen L. Radiographic identification of the primary medial knee structures. *J Bone Joint Surg Am.* 2009; 91:521–529.
15. Wijdicks CA, Griffith CJ, LaPrade RF, Spiridonov SI, Johansen S, Armitage BM, Engebretsen L. Medial knee injury. Part 2. Load sharing between the posterior oblique ligament and superficial medial collateral ligament. *Am J Sports Med.* 2009;37:1771–1776.